

Case Report

A case of chronic mesenteric ischemia managed by ascending aorta to superior mesenteric and hepatic artery bypass

Harilal V. Nambiar¹, Robin George Manappallil^{2*}, Sylesh Aikot³, Pramod V.⁴

¹Department of Cardio Thoracic and Vascular Surgery, Baby Memorial Hospital, Calicut, Kerala, India

²Department of Internal Medicine, Baby Memorial Hospital, Calicut, Kerala, India

³Department of Surgical Gastroenterology, Baby Memorial Hospital, Calicut, Kerala, India

⁴Department of Cardiac Anaesthesia, Baby Memorial Hospital, Calicut, Kerala, India

Received: 17 May 2017

Accepted: 17 June 2017

*Correspondence:

Dr. Robin George,

E-mail: drrobingeorgempl@gmail.com

Copyright: © the author(s), publisher and licensee Medip Academy. This is an open-access article distributed under the terms of the Creative Commons Attribution Non-Commercial License, which permits unrestricted non-commercial use, distribution, and reproduction in any medium, provided the original work is properly cited.

ABSTRACT

Chronic mesenteric ischemia is a rare and life-threatening condition which occurs due to occlusion of two or more mesenteric arteries following atherosclerosis. Multi-vessel revascularization forms the mainstay of treatment. This is a case of a middle-aged smoker who presented with abdominal angina and was diagnosed to have chronic mesenteric ischemia due to atherosclerotic occlusive aortic disease with coeliac artery and superior mesenteric artery occlusion. He was successfully managed with extra anatomic bypass from the ascending aorta to superior mesenteric and hepatic artery.

Keywords: Abdominal angina, Chronic mesenteric ischemia, Coeliac artery, Hepatic artery, Superior mesenteric artery

INTRODUCTION

Chronic mesenteric ischemia (CMI) is a rare and fatal cause of abdominal pain, resulting from the atherosclerotic stenosis of at least two mesenteric vessels. The diagnosis is often challenging, and patients usually present at the time of advanced disease. They are also subject to malnutrition and bowel infarction. Reduction of abdominal angina, prevention of bowel infarction and return to normal diet and nutrition are the main goals of treatment. Multi-vessel surgical recanalization of the celiac artery and the superior mesenteric artery (SMA) is the current line of management.¹⁻⁴ However, extensive atherosclerotic disease, complete vessel occlusion, or small calibre of arteries may be a hindrance to surgical vessel reconstruction. Poor nutrition along with multiple comorbidities are also matters of concern. Moreover, most of these patients would have been subject to previous abdominal surgeries or prior revascularization;

and the resultant scar tissue formation and adhesions make access to these vessels difficult.

CASE REPORT

A 50-year-old male, farmer by occupation, presented with history of post prandial diffuse colicky abdominal pain for the past 3 years, which has been progressive for 6 months. The pain was worsened by solid food. Over the past 1 year, he had lost about 10 kg. He is a known hypertensive on telmisartan 40 mg once daily. He was a chronic smoker (15-20 cigarettes/ day) for the past 20 years and an occasional alcoholic. He had undergone 4 surgeries in the past - left nephrectomy for renal artery stenosis, cholecystectomy and appendectomy for abdominal pain and fissurectomy for constipation. On examination, he was moderately build and nourished with stable vitals. His systemic examinations were normal. Considering his symptoms, a provisional diagnosis of

chronic mesenteric ischemia was made. His blood investigations like complete blood counts, renal and liver functions, electrolytes, HbA1c and TSH were normal. On computerized tomography (CT) scan evaluation, he was found to have atherosclerotic occlusion of the entire thoracic aorta along with celiac artery and SMA (Figure 1), thereby confirming the diagnosis of chronic mesenteric ischemia. ANA profile, p and c ANCA were negative. Chest X-ray, electrocardiogram, echocardiography and coronary angiogram were normal.

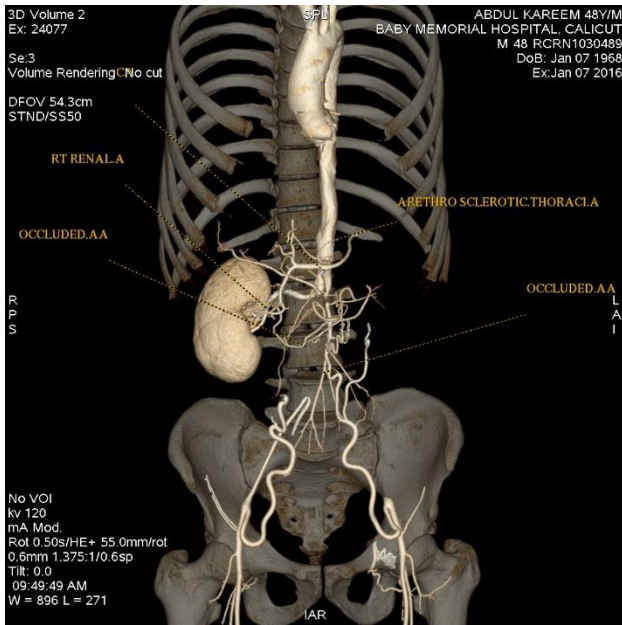


Figure 1: CT scan showing atherosclerotic occlusive aortic disease with celiac artery and SMA occlusion.

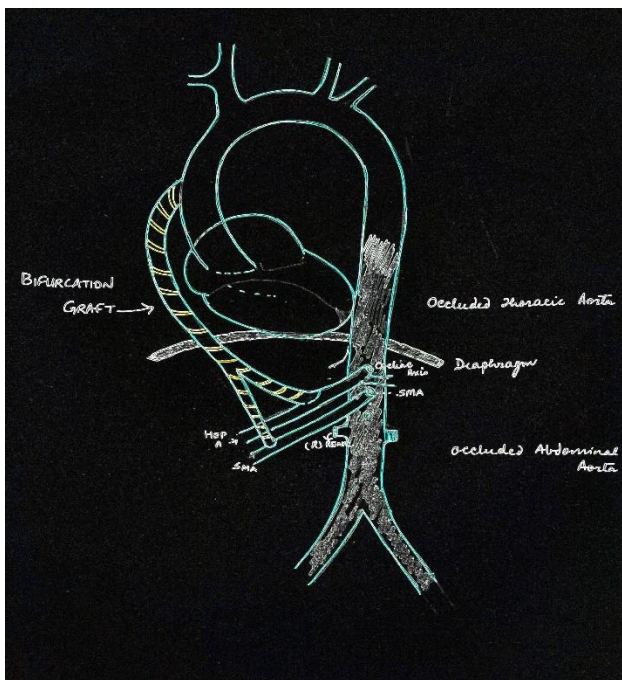


Figure 2: Surgical plan of extra-anatomic ascending aorta to SMA and hepatic artery bypass.

Surgical plan

Extra-anatomic ascending aorta to SMA and hepatic artery bypass (Figure 2). (Due to the extensive disease state, interventional radiology was not possible).

Procedure

Epidural and general anaesthesia were used. Median sternotomy and midline laparotomy was done (as the ascending aorta, SMA and hepatic artery can be accessed more easily). The diaphragm was left intact. A Dacron graft (16x8x8mm) was used for aortic bifurcation. Proximal anastomosis was attained by end to side to ascending aorta on partial clamp using 4-0 prolene continuous sutures. There was size mismatch between the smallest available bifurcation graft and the size of SMA and hepatic artery. This was circumvented by autologous saphenous vein interposition between the graft and target vessels. The graft was tunneled retrosternal across the diaphragm, just behind the anterior abdominal wall into already exposed SMA and common hepatic artery. Two segments of 4.5mm saphenous vein was anastomosed end to side to SMA and common hepatic artery respectively (using 7-0 prolene). These two saphenous vein graft segments were further anastomosed end to end to each limb of bifurcating Dacron graft using 6-0 prolene. The end result was the achievement of a good revascularization to the entire gastrointestinal tract. Since revascularization of both legs was not an emergency due to development of collaterals, a bilateral axillofemoral bypass grafting was planned as a next step procedure. His post-operative period was uneventful. His bowel sounds reappeared after 48 hours and oral feeds were started. He was fully ambulant and by day 5 he could take solid food. He was put on tablet clopidogrel (150 mg once daily) post operatively and was discharged successfully on day 12 of admission.

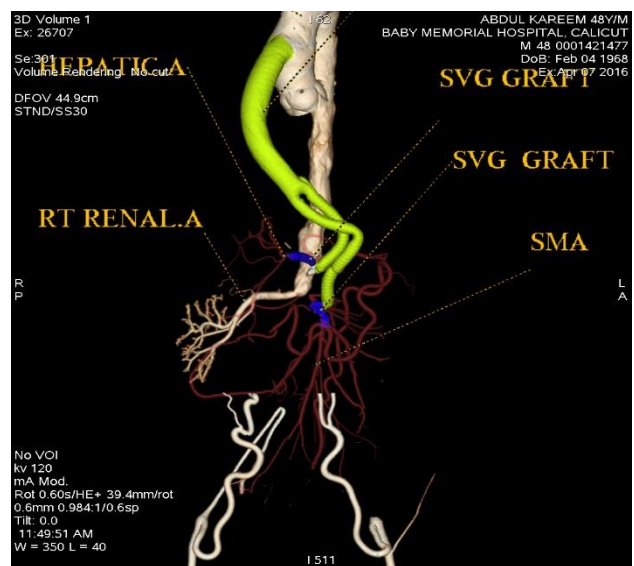


Figure 3: Post-operative CT scan after 2 months.

His repeat CT abdomen after 2 months showed good revascularization (Figure 3) and on 8 months review, he continued to do well with about 8kg weight gain.

DISCUSSION

CMI is a rare condition. The symptoms like post prandial abdominal pain and unexplained weight loss should raise it suspicion. Abdominal angina occurs when the blood vessels can no longer compensate for the increased post prandial demand by the gastrointestinal tract.¹

In this case, the patient was a chronic smoker who presented with post prandial abdominal pain and weight loss. He had undergone several abdominal surgeries in various hospitals for the same complaints, but continued to be symptomatic. It was at this point that a CT evaluation revealed thrombotic occlusion of mesenteric vessels and was managed successfully by an extra-anatomic ascending aorta to SMA and hepatic artery bypass surgery.

Owing to the rarity of the disease, no guidelines regarding revascularisation technique has been outlined. The best surgical approach would be to minimize the risk of recurrent ischemia by doing a multi-vessel revascularization of the SMA and celiac arteries. A 5 year patency rate of more than 85% has been achieved with aorto-mesenteric bypass or transaortic mesenteric endarterectomy.² Senadhi reported a case of CMI due to fibromuscular dysplasia causing SMA stenosis, which was corrected with angioplasty and stenting.⁵ Van De Winkel et al managed a case of SMA occlusion causing partial jejunal ischemia by resecting the stenotic ischemic jejunal segment and performing an end-to-end anastomosis.⁶ A case of acute exacerbation of CMI was managed by surgical retrograde bypass to the gastroduodenal artery using a saphenous vein graft by Abe et al.⁷

CONCLUSION

Due to its uncommon presentation, CMI continues to be a diagnostic challenge. The symptoms like unexplained weight loss and post prandial abdominal angina are some of the valuable clues. Poor nutritional status and other comorbid conditions are also obstacles in the

management. Moreover, no specific guidelines regarding treatment have been outlined. In this case, the thrombotic mesenteric occlusion was successfully managed by extra-anatomic ascending aorta to SMA and hepatic artery bypass surgery.

Funding: No funding sources

Conflict of interest: None declared

Ethical approval: Not required

REFERENCES

1. Kilsby A, Pasha Y. Chronic mesenteric ischaemia: a battery of negative tests in a patient with episodic abdominal pain, weight loss and diarrhoea. *BMJ Case Rep.* 2013;2013.
2. Cunningham CG, Reilly LM, Rapp JH, Schneider PA, Stoney RJ. Chronic visceral ischemia: three decades of progress. *Ann Surg.* 1991;214(3):276-88.
3. McMillan WD, McCarthy WJ, Bresticker MR, Pearce WH, Schneider JR, Golan JF, et al. Mesenteric artery bypass: objective patency determination. *J Vasc Surg.* 1995;21(5):729-40.
4. Johnston KW, Lindsay TF, Walker PM, Kalman PG. Mesenteric arterial bypass grafts: early and late results and suggested surgical approach for chronic and acute mesenteric ischemia. *Surg.* 1995;118(1):1-7.
5. Senadhi V. A rare cause of chronic mesenteric ischemia from fibromuscular dysplasia: a case report. *J Med Case Reports.* 2010;4:373.
6. Van De Winkel N, Cheragwandi A, Nieboer K, van Tussenbroek F, De Vogelaere K, Delvaux G. Superior mesenteric arterial branch occlusion causing partial jejunal ischemia: a case report. *J Med Case Reports.* 2012;6:48.
7. Abe S, Yamakawa T, Kawashima H, Yoshida M, Takanashi S, Kashiya M. Surgery for acute exacerbation of chronic mesenteric ischemia: a case report. *Surg Case Rep.* 2016;2:146.

Cite this article as: Nambiar HV, Manappallil RG, Aikot S, Pramod V. A case of chronic mesenteric ischemia managed by ascending aorta to superior mesenteric and hepatic artery bypass. *Int Surg J* 2017;4:2836-8.