

Case Report

A case of ectopic testis: an intraoperative enigma

Veershetty S. D.*, Manjunath K., O. G. Prakash, K. S. Hanumanthaiah, Rajagopalan S.

Department of General Surgery, RajaRajeswari Medical College and Hospital, Bengaluru, Karnataka, India

Received: 26 December 2017

Received: 10 January 2018

Accepted: 30 January 2018

***Correspondence:**

Dr. Veershetty S. D.,

E-mail: veer5918@gmail.com

Copyright: © the author(s), publisher and licensee Medip Academy. This is an open-access article distributed under the terms of the Creative Commons Attribution Non-Commercial License, which permits unrestricted non-commercial use, distribution, and reproduction in any medium, provided the original work is properly cited.

ABSTRACT

Author present a case of persistent mullerian duct syndrome with transverse testicular ectopia with bilateral hernia uteri inguinalis in a 17 years old boy. This is a rare congenital anomaly and an uncommon form of male pseudo-hermaphroditism characterized by the persistence of well-developed Mullerian duct structures in an otherwise normal male with a 46 XY karyotype. Transverse testicular ectopia (TTE) is one of the rarest forms of testicular ectopia. In this condition, both testes are located on one inguinal side and the opposite inguinal canal and scrotum are empty. TTE associated with PMDS is much rarer. The exact cause of PMDS is uncertain. However, it is thought to result from the failure of synthesis or release of Mullerian inhibiting factor (MIF), the failure of end organs to respond to MIF, or a defect in the timing of the release of MIF. Patients with PMDS present with unilateral or bilateral cryptorchidism and an inguinal hernia containing a fallopian tube, uterus and testis. The case was diagnosed on doing diagnostic laparoscopy followed by bilateral inguinal herniorrhaphy and right Orchidectomy.

Keywords: Cryptorchidism, Hernia uteri inguinalis, Pseudo-hermaphroditism, Persistent mullerian duct syndrome, Transverse testicular ectopia, Wolffian duct

INTRODUCTION

In 1895, Jordan et al described the first case of PMDS associated with testicular transverse ectopia (TTE).¹ Bilateral fallopian tubes and a uterus occur with an otherwise normal phenotype, normal external male genitalia, commonly bilateral cryptorchidism and normal Wolffian duct structures. Approximately 150 cases of PMDS were reported, whereas Hernia Uteri Inguinalis is even rare.² Familial association has been found in some cases. Cases are usually discovered during surgery for an inguinal hernia or cryptorchidism, or by the presence of transverse testicular ectopia (one of the rarest form of testicular ectopia). These cases are diagnosed incidentally during diagnostic laparoscopy/laparotomy for undescended testis or inguinal hernia.

CASE REPORT

A 17 years old boy presented with absent testis on right side since childhood and pain abdomen for 7 days. External genitalia examination revealed well developed left hemiscrotum with left testis, rudimentary right hemiscrotum with absent right testis, well developed penis and pubic hairs.

Secondary sexual characters like moustache, axillary hair, deep voice and other masculine features makes patient male phenotypically. And all developments were normal for his chronological age. Abdomen was soft, non-tender with no palpable mass. Hernial orifices were intact. USG abdomen, pelvis and scrotum showed normal abdominal study, normal left testis in left scrotum, left sided hernia

with omentocele. Right testis couldn't be visualized. As location of right testis was not made out on USG, MRI had been suggested for its localization and it showed both testis in left hemiscrotum with left inguinal hernia (bowel loops/ omentum as its content and bilateral inguinal lymphadenopathy.



Figure 1: Undescended right testis with hemiscrotum.

epididymis with efferent ductules, Persistent Mullerian duct structures with uterus and fallopian tube, vas deferens in uterine parametrium and glandular structures resembling seminal vesicle embedded in uterine wall seen.

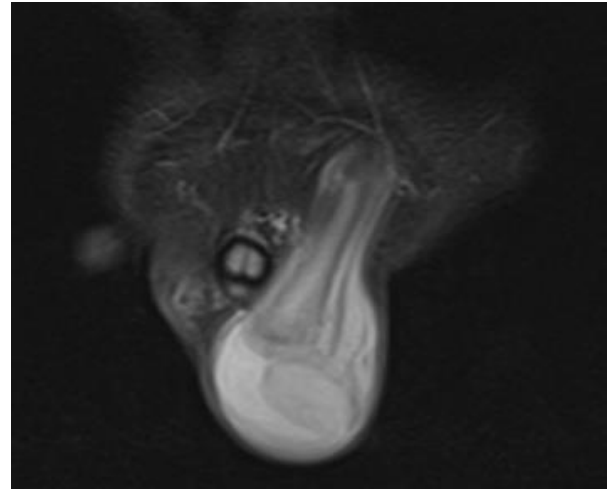


Figure 2: Hernia from inguinal canal.

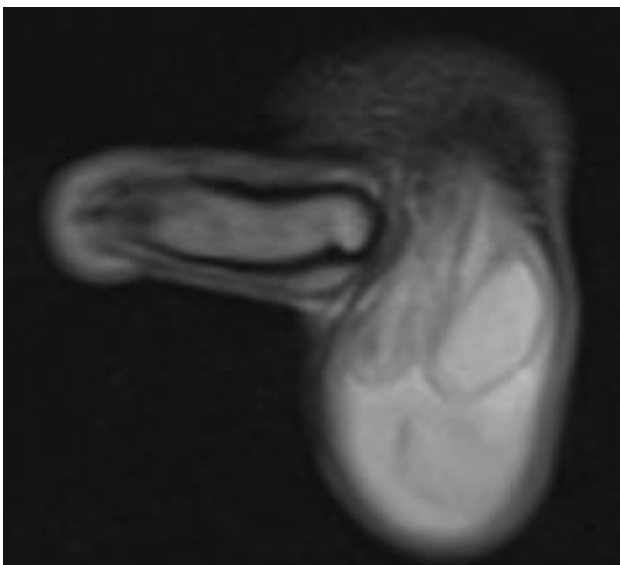


Figure 2: Both testis in the same hemiscrotum.

Diagnostic laparoscopy detected a mass near the left deep inguinal ring. Procedure was changed to open and the mass was noticed to be resembling uterus and bilateral fallopian tubes. Another mass was also visualised originating from the deep inguinal ring. Both masses were removed and sent for histopathological examination to confirm the enigmatic structures found. In the right inguinal canal, a sac was made out so right sided Orchidectomy with bilateral inguinal herniorrhaphy was carried out.

Histopathological examination revealed Testicular atrophy with complete maturation arrest with no evidence of neoplasia. Sertoli cells, Leydig cell hyperplasia,

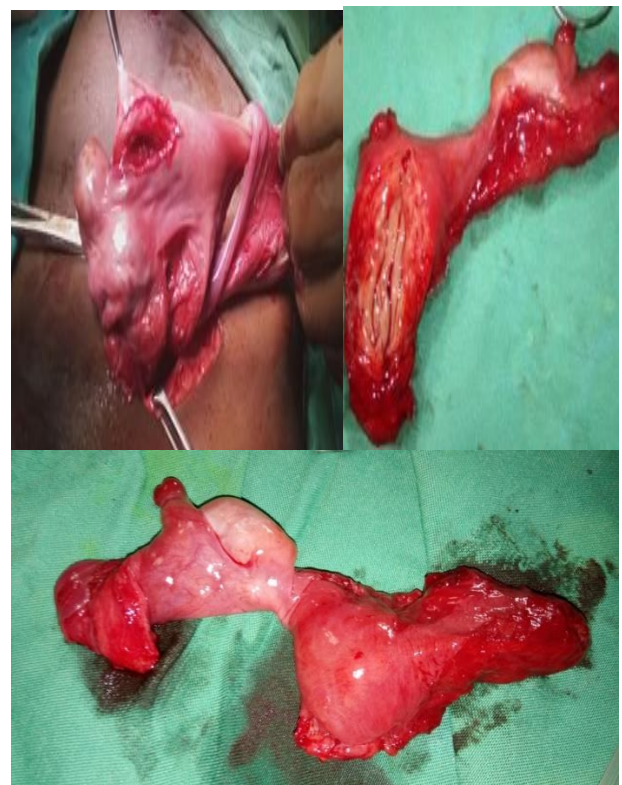

Figure 4: Uterine structure found during surgery.

DISCUSSION

At the eighth week of gestation, the embryo has both male and female primordial genital ducts (the Wolffian and Mullerian) as paired structures and the external genitalia have not formed yet. Mullerian duct derivatives are present in a male fetus up to 8th week of gestation and

regression is mediated by Mullerian Inhibiting Factor (MIF) produced by Sertoli cells. Failure of synthesis or release of MIF or defect in end organs or an error in the timing of release of MIF causes persistence of Mullerian structures, the condition being known as Persistent Mullerian Duct Syndrome. If the Mullerian structures are relatively immobile, testicular descent may be impeded.^{3,4} Patients usually present with absent cryptorchidism on one side (usually on right). Persistent Mullerian Duct Syndrome must be distinguished from mixed gonadal dysgenesis, which is characterized by ambiguous genitalia with unilateral testis and a streak gonad contralaterally, with persistence of Mullerian duct structures on the side of the streak. These patients usually show chromosome mosaicism of XO/XY. Cryptochord testis are associated with genitourinary anomalies in 13% of cases; cryptorchidism and hypospadias are associated with ambiguous genitalia in 53% and with intersex problems in 27% of cases.⁵ The rarest of all varieties of cryptorchidism is the transverse type, in which both gonads migrate through one inguinal canal, usually the left, towards the same hemiscrotum; the opposite inguinal canal and scrotum are empty.⁶

Diagnosis is made incidentally during surgical exploration for cryptorchidism or herniorrhaphy, as the Mullerian remnants are not palpable on abdominal, rectal or scrotal examination. Although Sloan and Walsh documented radiographically, such evaluation is not routinely helpful in these patients. Treatment is Orchidectomy with repair of associated hernia if any.

Funding: No funding sources
Conflict of interest: None declared
Ethical approval: Not required

REFERENCES

1. Martin EL, Bennett AH, Cromie WJ. Persistent Mullerian duct syndrome with transverse testicular ectopia and spermatogenesis. *J Urol.* 1992;147:1615-7.
2. Loeff DS, Imbeaud S, Reyes HM, Meller JL, Rosenthal IM. Surgical and genetic aspects of persistent mullerian duct syndrome. *J Pediatr Surg.* 1994;29:61-5.
3. Dekker HM, de Jong IJ, Sanders J, Wolf RF. Persistent mullerian duct syndrome. *Radiographics.* 2003;23:309-13.
4. Clemente A, Macchi V, Berretta M, Morra A. Female form of persistent müllerian duct syndrome: MDCT findings. *Clin Imaging.* 2008;32:314-7.
5. Stocker JT, Dehner CP. Paediatric pathology. In *Selly DMed, sexual maldevelopment syndromes.* Philadelphia: JB Lippincott. 1992:117-9.
6. Brown AF, Black N. unilateral double testes or transverse ectopia of testes. *Can med Assoc J.* 1960;82:84-5.

Cite this article as: Veershetty SD, Manjunath K, Prakash OG, Hanumanthaiah KS, Rajagopalan S. A case of ectopic testis: an intraoperative enigma. *Int Surg J* 2018;5:1127-9.