

## Case Report

# A case of left undescended testis with ipsilateral ectopic kidney

Arti Mitra, Prenoy Araujo, Unmed Chandak\*

Department of Surgery, Govt Medical College, Nagpur, Maharashtra, India

**Received:** 14 November 2018

**Accepted:** 11 December 2018

**\*Correspondence:**

Dr. Unmed Chandak,

E-mail: [uachandak@gmail.com](mailto:uachandak@gmail.com)

**Copyright:** © the author(s), publisher and licensee Medip Academy. This is an open-access article distributed under the terms of the Creative Commons Attribution Non-Commercial License, which permits unrestricted non-commercial use, distribution, and reproduction in any medium, provided the original work is properly cited.

### ABSTRACT

Undescended testis is one of the most common congenital anomalies in newborns. Incidence of this is anywhere between 1.6% and 9.0%. The incidence dramatically drops to 0.9-1.8% at 3 months of age. This is due to the spontaneous descent of the testes. The complications of undescended testes are infertility and malignant transformation. A 29-year-old unmarried male patient came to the hospital with complained of absent of left testis within scrotal sac since birth and a left inguinal swelling since 1 year with no other complaints. On examination, the left scrotal sac was empty. The right side scrotum was normal and testis was palpable within scrotal sac. On USG, examination findings were confirmed Left testis seen in relation to lower pole of left kidney in left inguinal region with normal echo texture s/o left ectopic testis. Left kidney in pelvic region at paramedian location with hilum facing anteromedially s/o left ectopic kidney. Early diagnosis and surgical intervention is key so as to preserve the undescended testis and prevent malignant change or infertility problems. It is imperative that all tests be done to assess kidney function.

**Keywords:** Kidney, Paramedian, Scrotal sac, USG

### INTRODUCTION

Renal ectopia is a condition in which the mature kidney fails to reach its normal location in the renal fossae and has been known to exist since the sixteenth century. In autopsy series, the incidence is about 1 in 900. The ectopic kidney may be cranial or caudal to its usual position. Caudal renal ectopia is of three types viz. abdominal, lumbar or pelvic. The pelvic ectopic kidney is situated below the horizontal level of the pelvic crest. Pelvic ectopia has been seen in 1 in 2100 autopsies and solitary pelvic kidney in 1 in 22000 autopsies.<sup>1</sup> Renal ectopia may be associated with other congenital anomalies.<sup>2</sup> We report a patient with a solitary pelvic ectopic kidney and ipsilateral ectopic testes presenting as renal failure.

Undescended testis is one of the most common congenital anomalies in newborns. Incidence of this is anywhere

between 1.6% and 9.0%.<sup>3</sup> The incidence dramatically drops to 0.9-1.8% at 3 months of age. This is due to the spontaneous descent of the testes. The complications of undescended testes are infertility and malignant transformation.

Renal agenesis is an uncommon congenital anomaly. Bilateral renal agenesis is incompatible with life. Unilateral renal agenesis has been found in 1 in every 1000 autopsies. It typically presents as part of a syndrome which involves vertebral defects, anorectal atresia, cardiovascular or tracheo esophageal anomalies.<sup>4</sup>

Renal agenesis has been associated with genital abnormalities in 20-70% of the cases. In males, many anomalies have been reported like seminal vesicle cysts and an ectopic drainage of the ureter.<sup>5</sup> In very few cases have renal agenesis been reported to be associated with undescended testis.

## CASE REPORT

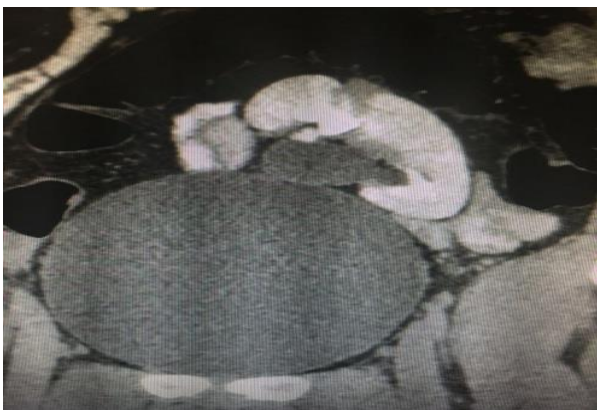A 29-year-old unmarried male patient came to the hospital with complained of absent of left testis within scrotal sac since birth and a left inguinal swelling since 1 year with no other complaints. On examination, the left scrotal sac was empty. The right side scrotum was normal and testis was palpable within scrotal sac (Figure 1).



**Figure 1: On inspection in standing position empty left scrotal cavity.**

On USG, examination findings were confirmed Left testis seen in relation to lower pole of left kidney in left inguinal region with normal echo texture s/o left ectopic testis. Left kidney in pelvic region at paramedian location with hilum facing anteromedially s/o left ectopic kidney.

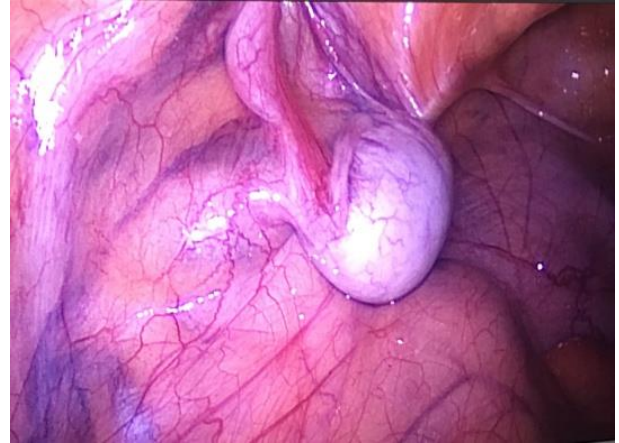
CT scan A+P s/o left testis is not visualised in left scrotal cavity. There is well defined homogenously enhancing structure in left iliac fossa, 1 inch superior and lateral to mid inguinal point, left ectopic testis. Left kidney is also ectopic position lying in L4-L5 is malrotated in position within pelvis rotated medially. All biological markers are within normal rang (Figure 2-5).



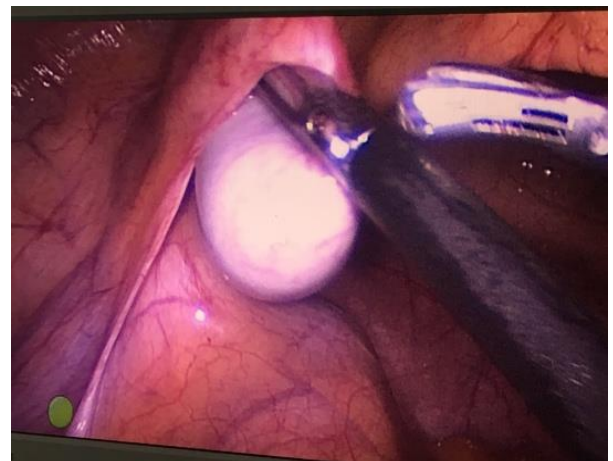
**Figure 2: On CECT abdomen and pelvis s/o left ectopic testis with ipsilateral kidney.**

The patient was scheduled for laparoscopic left orchiectomy so as to prevent the risk of malignant

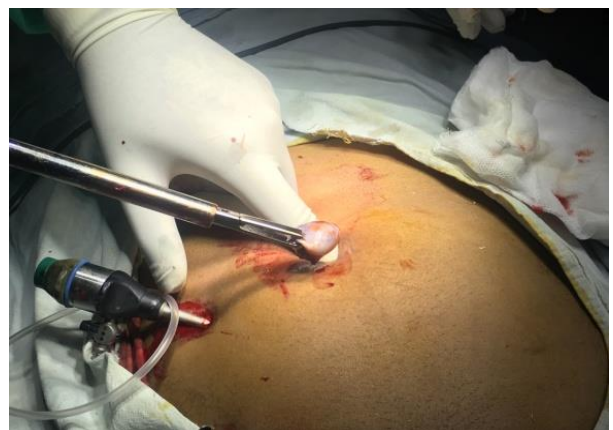transformation. The surgery was uneventful, and the patient was doing well post-operatively. On HPE testicular tissue- seminiferous tubules containing only sertolis cells with no spermatogenesis. No foci of intertubular germ cell neoplasia and malignant change in the specimen.



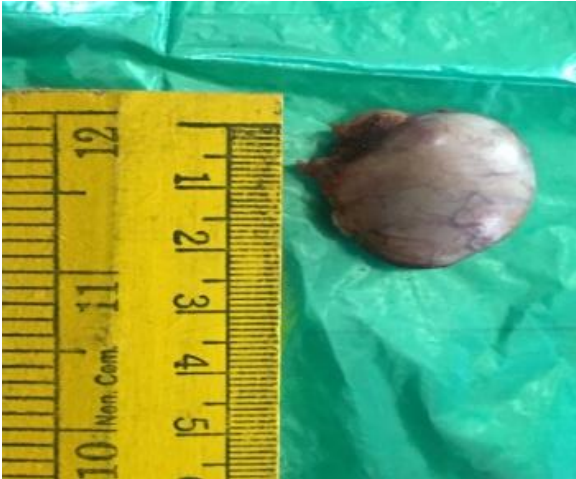**Figure 3: On laparoscopic view showing ectopic left testis.**



**Figure 4: Laparoscopic excision of left testis with help harmonic.**



**Figure 5: Umbilical port site removal of left testis.**



**Figure 6: Excised left testis.**

## DISCUSSION

Renal ectopia is being noted with greater frequency in recent times due to increasing use of imaging techniques to visualise the urinary tract (including prenatal period). The ectopic kidney is generally smaller than normal with persistence of fetal lobulations.<sup>6</sup> Anomalous vasculature is usually the rule in such kidneys. Due to incomplete rotation of the kidney, the renal pelvis is usually anterior to the parenchyma.<sup>7</sup> More than half of the ectopic kidneys have a hydronephrotic collecting system. The obstruction may be at the ureteropelvic or ureterovesical junction often due to vascular compression of the ureter. Vesicoureteric reflux is also quite common in the ectopic kidney. Besides the ectopic kidney is prone for stone formation and recurrent urinary tract infections.<sup>8</sup>

Congenital defects of the contralateral kidney are also common. Hydronephrosis secondary to obstruction or reflux may be seen in 25% of the nonectopic contralateral kidney. Agenesis of the contralateral kidney has also been reported 2-4 Most cases are usually asymptomatic.<sup>9</sup>

Abdominal pain suggestive of renal colic is the most frequent symptom leading to diagnosis of renal ectopia. Renal ectopia may also present initially with urinary tract infection or a palpable abdominal mass.<sup>10</sup>

The gold standard for diagnosis of a solitary kidney after detection on a USG is magnetic resonance urography. All these tests were not done for the patient as it was not available at the time of patient admission, and the patient was unwilling for further evaluation at that point. The patient was informed about the importance of regular follow-up in the future to evaluate his renal function and to detect early and treat, any derangement of his renal function. He was asked to avoid taking any nephrotoxic drugs.

## CONCLUSION

Early diagnosis and surgical intervention are key so as to preserve the undescended testis and prevent malignant change or infertility problems. It is imperative that all tests be done to assess kidney function.

*Funding: No funding sources*

*Conflict of interest: None declared*

*Ethical approval: Not required*

## REFERENCES

1. Virtanen HE, Toppari J. Epidemiology and pathogenesis of cryptorchidism. Hum Reprod Update. 2008;14:49-58.
2. Cascio S, Paran S, Puri P. Associated urological anomalies in children with unilateral renal agenesis. J Urol. 1999;162:1081-3.
3. Trigaux JP, Van Beers B, Delchambre F. Male genital tract malformations associated with ipsilateral renal agenesis: Sonographic findings. J Clin Ultrasound. 1991;19:3-10.
4. Thompson DP, Lynn HB. Genital anomalies associated with solitary kidney. Mayo Clin Proc. 1966;41:538-48.
5. Onwuchekwa RC, Sapira MK, Onwuchekwa AC. Unilateral renal agenesis coexisting with bilateral cryptorchidism in an adult Nigerian: Case report. Niger Med J. 2009;50:71-3.
6. Van Blerk PJ. The kidneys, ureters and adrenals. In: Decker GA, du Plessis DJ, editors. Lee McGregor's Synopsis of Surgical Anatomy. 12th ed. Indian edition. Mumbai: K.M. Varghese Company; 1986:297.
7. Bauer SB. Anomalies of the kidney and ureteropelvic junction, in Cambell's Urology, seventh edition, eds. Walsh PC, Retik AB, Vaughan ED Jr, Wein AJ, Philadelphia. WB Saunders Company; 1998:1708-55.
8. Thompson GP, Pace JM. Ectopic kidney: A review of 97 cases. Surg Gynecol Obstet. 1937;64:935.
9. Gleason PE, Kellalis PP, Husmann DA, Kramer SA. Hydronephrosis in renal ectopia: Incidence, etiology and significance. J Urol. 1994;151:1660.
10. Boujnah H, Abid I, Moalla N, Zmerli S. Pelvic kidney Apropos of 50 cases. Ann Urol Paris. 1989;23:11-6.

**Cite this article as:** Mitra A, Araujo P, Chandak U. A case of left undescended testis with ipsilateral ectopic kidney. Int Surg J 2019;6:304-6.