

## Original Research Article

# Giant retrosternal goiter masquerading as, right posterior mediastinal mass: a rare case report

Jaykumar N. Punjani<sup>1</sup>, Kesha K. Shah<sup>1</sup>, Arun Kumar Haridas<sup>2\*</sup>

<sup>1</sup>Department of General Surgery, <sup>2</sup>Department of Cardiovascular and Thoracic Surgery, C.U. Shah Medical College and Hospital, Surendranagar, Gujarat, India

**Received:** 08 November 2019

**Accepted:** 12 December 2019

### \*Correspondence:

Dr. Arun Kumar Haridas,

E-mail: [arunkumarharidas@gmail.com](mailto:arunkumarharidas@gmail.com)

**Copyright:** © the author(s), publisher and licensee Medip Academy. This is an open-access article distributed under the terms of the Creative Commons Attribution Non-Commercial License, which permits unrestricted non-commercial use, distribution, and reproduction in any medium, provided the original work is properly cited.

### ABSTRACT

Complete mediastinal plunging thyroid gland is a rare entity, accounting for 1% of all mediastinal tumours, particularly posterior mediastinal tumour much more rare. We would like to present, a 30-year-old lady presented to ENT department with neck swelling and its further investigation shown to be giant posterior mediastinal mass. Thyroid function tests were normal. CT scans of the neck and chest revealed a large right mediastinal mass compressing the trachea from the right side and extending to the superior part of the posterior mediastinum with enlarged right thyroid gland in the cervical position. Midline extended sternotomy was done for complete surgical excision of the mass along with right hemi thyroidectomy. It was well circumscribed, capsulated, multinodular firm inconsistency, and vascular. Histopathology revealed thyroid tissue negative for malignancy. Giant plunging thyroid in the mediastinum is very rare. It should be differentiated from other mediastinal mass. The plunging goiter in posterior mediastinum is surgically challenging. Transsternal surgical removal is the treatment of choice in such cases.

**Keywords:** Mediastinal masses, Thyroid, Goitre, Ectopic thyroid, Retrosternal thyroid

### INTRODUCTION

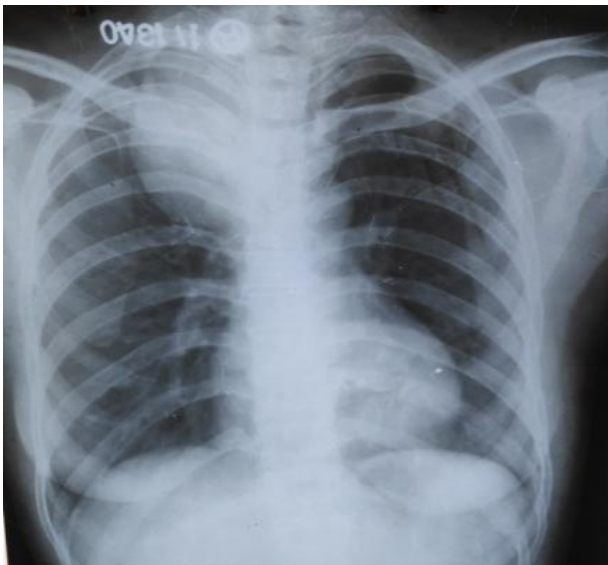
Most retrosternal goitre is situated in the anterior mediastinal compartment, but according to the literature, only 10–15% is located in the posterior mediastinum.<sup>1,2</sup> The primary mediastinal goitre (PMG) are very uncommon, few cases were reported in the literature. Giant mediastinal thyroid gland is a rare entity and accounts for approximately 1% of all mediastinal tumours.<sup>3</sup> A thyroid mass is not an unusual finding below the thoracic inlet but presenting posterior mediastinal mass very rare and majority reported so far were in anterior mediastinum. It should be considered in the differential diagnosis and workout of all mediastinal masses. Even ectopic or primary thyroid glands generally occur in the midline anterior mediastinum as a result of abnormal median migration, and their presence lateral to

the midline is rare.<sup>4</sup> The differential diagnosis of the mass in the paratracheal position extending into the mediastinum included teratoma and germ cell tumours, sub sternal goitre, Castleman's disease, and neurologic tumours. Indeed, substernal goitre excluded after the computed tomography (CT) scan by clear separation between the mass and the right thyroid lobe. Most retrosternal goitre can be resected through a trans cervical approach, those extending beyond the aortic arch into the posterior mediastinum are better dealt with by either sternotomy or lateral thoracotomy with minimal morbidity and no mortality

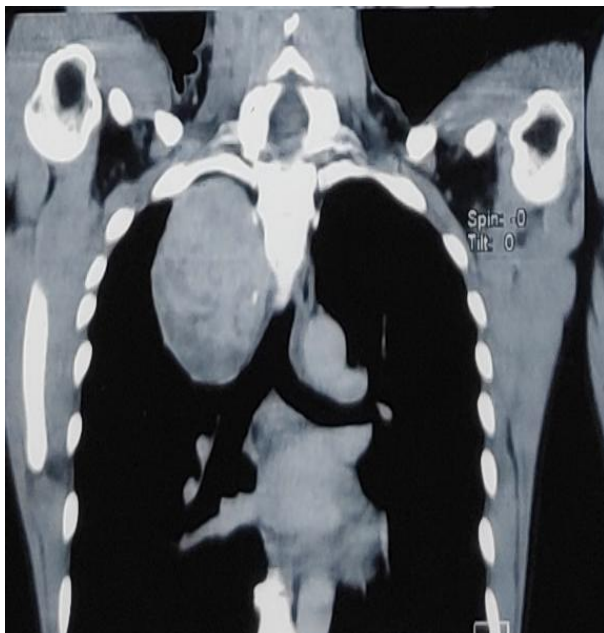### CASE REPORT

A 30 year old female normotensive, non-diabetic, euthyroid status came with complains of swelling on right

side of neck for last 10 years. Swelling which was initially small and gradually progressive in size with no voice change. She had breathlessness in supine position. Further evaluation, patient found to have right posterior mediastinal mass measuring 15×10×10 cm, on X-ray (Figure 1) and CT scans (Figure 2) of the chest. It was well-circumscribed mediastinal mass compressing and kinking the trachea from the right side and extending into the superior part of anterior and posterior mediastinum. Patient had no past surgical history and had no family history of cancer, genetic diseases or similar illness. The indirect laryngoscopy was done as preoperative routines for patient. Vocal cords found to be normal. Preoperative fine needle aspiration cytology of thyroid was done which shows colloid goiter.

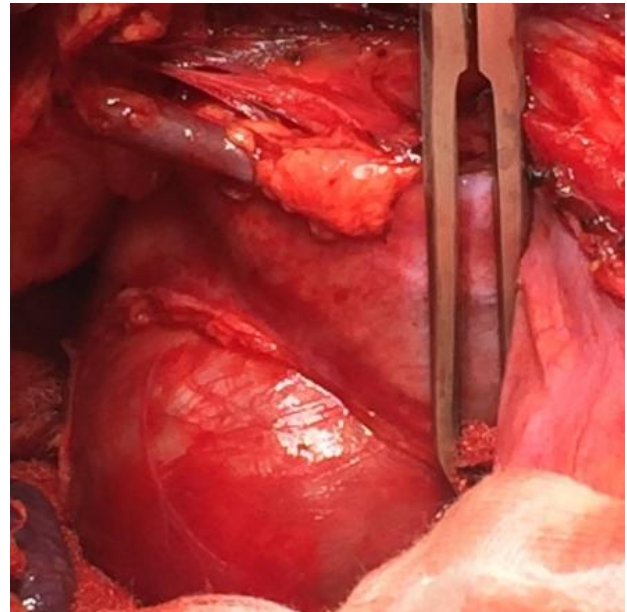


**Figure 1: Chest X-ray postero-anterior view.**

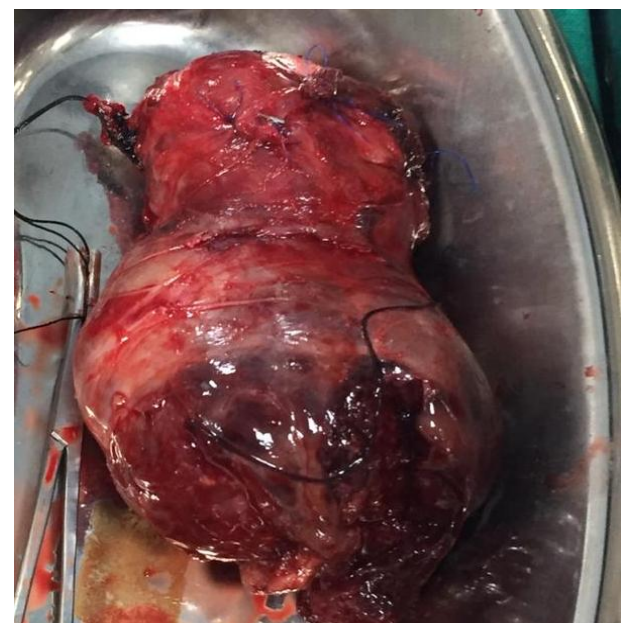


**Figure 2: High resolution CT of chest.**

Patient was vitally stable and afebrile. Local examination of the neck showed right palpable thyroid gland. CBC, LFT and RFT were within normal limit. Thyroid Function Tests were within normal limit. Chest X-ray and CT scan of the neck and chest revealed neck and mediastinal swelling. Taking into account of clinical symptoms of a mediastinal mass, we removed it surgically, through an extended transsternotomy.



**Figure 3: Mediastinal mass.**

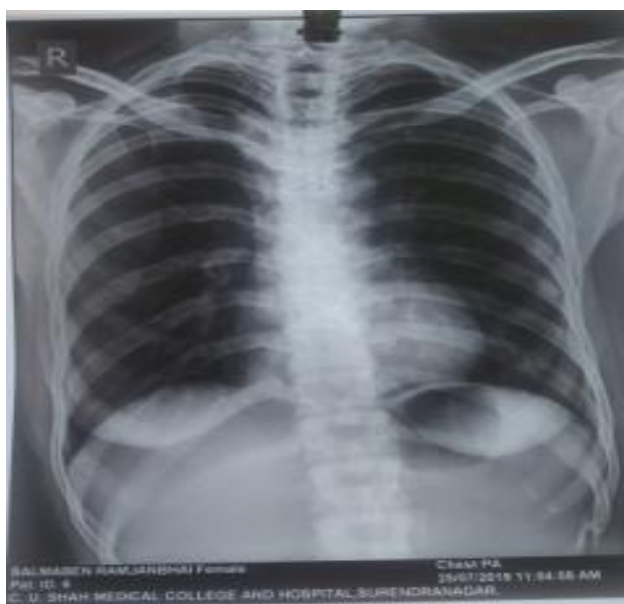

**Figure 4: Excised specimen.**

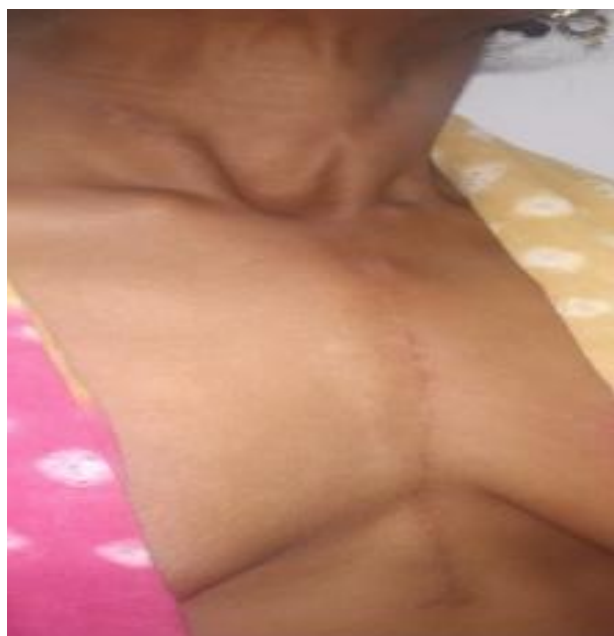#### *Surgical technique*

Surgical excision of the mass was planned to confirm the diagnosis and alleviate the pressure symptoms. Extended mid line sternotomy was done. A big mediastinal mass

was found to compress the trachea from the right side, extending into the superior part of the anterior, middle and posterior mediastinum. It measured 15×10×10 cm, well encapsulated (Figure 3). The mass was well circumscribed, multinodular, and firm in consistency. The mediastinal mass was in continuation with right lobe of thyroid. The right thyroid lobe was plunging in to the retrosternal area. The mass then passing posterior to superior vena cava and innominate vein, finally was settled in the right posterior mediastinum. Minimal adhesion to the right upper lobe of lung, were seen. Lots of vascular feeders were arising from right hilum found but there was no bony destruction or bony lesion. There was no pleural effusion.



**Figure 5: Postoperative X-ray.**



**Figure-6 Post-operative scar.**

Dissection of the mass was done from the SVC, innominate vein, common carotid artery and other surrounding structures. The mediastinal mass pulled out to cervical area followed by right hemi thyroidectomy done in continuation (Figure 4). Histopathology of the mass confirmed it as colloid goitre and negative for malignancy. Postoperative X-ray showed complete clearance and good lung expansion (Figure 5) and wound healed well (Figure 6).

## DISCUSSION

Most retrosternal goitre is situated in the anterior mediastinal compartment, less than 10-15% is located in the posterior mediastinum.<sup>1,2</sup> The sub sternal goitre is usually defined as a thyroid formation with cervical departure that goes beyond the superior thoracic inlet for at least 3 cm. It preserves the connection between the thoracic and cervical portions receiving blood supply from the neck. The “forgotten” goitre is an extremely rare disease in which a mediastinal thyroid mass is found after total thyroidectomy. It descends directly into the visceral compartment surrounded by the pretracheal fascia and only reaches the anterior mediastinum after reaching a huge size.

In 1940, the seminal report of Wakeley and Mulvany divided intrathoracic thyroid masses into 3 types; (1) small substernal extension (2) partial intrathoracic and (3) complete in which all of the mass lies within the thoracic cavity. It has been found that 80% of the substernal thyroid masses are of small extension type, 15% are of the partial type and 2-4% is of the complete type.<sup>1</sup>

Long-standing huge goitres are common in iodine-deficient endemic areas. The majority of the patients are symptomatic or clinic radiological evidence of airway involvement. The incidence of dyspnoea, airway deformity, obstruction, intubation difficulty and tracheomalacia is high with huge goiters. Substernal enlargement of a goiter can cause compression of several mediastinal structures including the trachea, esophagus and superior vena cava. These symptoms indicates urgent resection of the mass.<sup>3</sup>

Differential diagnoses with other diseases, such as lymphomas, thymic tumors and dermoid cysts mandatory. In fact each one needs different management and treatment. The commonest mediastinal tumours are lymphomas, germ-cell tumours, substernal goiter and neurogenic tumours and Castleman’s disease. Ectopic thyroid in the thorax without connection to the original gland in the neck is very rare, and only a few cases have been reported in the literature. It is also important to differentiate between substernal goiter, ectopic thyroid, and forgotten goiter. Benign mediastinal tumours are usually asymptomatic, euthyroid and are found incidentally. Surgical intervention should always be considered in the course of diagnosing the nature of the mediastinal mass even in elderly patients. This is because

of the, high risk of tracheal compression and the low morbidity of the surgery.<sup>1,3,4</sup>

Radiological imaging studies such as ultrasound, CT scan and magnetic resonance imaging may be helpful in knowing the extension of thyroid, but the best diagnostic test for isolated mediastinal thyroid is thyroid scanning with technetium-99m. Tissue biopsy can be performed using many methods such as CT-guided fine needle aspiration, EBUS-transbronchial needle aspiration or surgical excision.<sup>5</sup>

Surgical resection is the gold standard treatment. Its role is both diagnostic and therapeutic, it allows diagnosis by providing tissue for histological study, it also allows to rule out malignancy and to remove compression of adjacent structures, such as trachea and heart to prevent the risk of tracheomalacia, heart rhythm disorders.<sup>6</sup> Machado et al noticed that most retrosternal goiters can be resected through a transcervical approach, but those extending beyond the aortic arch into the posterior mediastinum are better dealt with by sternotomy or lateral thoracotomy. Kilic et al recommend the use of extended approaches, such as median sternotomy and thoracotomy for retrosternal goiter for surgical exposure, because they provide a wide exposure, facilitate removal of the mass and avoid catastrophic results, such as haemorrhage. Sternotomy is generally accepted as the most adequate approach for the removal of mediastinal thyroid goiters of the anterior and posterior mediastinum.<sup>7-9</sup>

Postoperative mortality and morbidity is very low, independent of surgical techniques. Other surgical approaches for excision of a posterior mediastinal thyroid goiter reported in literature are video-assisted thoracoscopic surgery techniques, Robotic-assisted technique for the removal of a substernal thyroid goiter, with extension into the posterior mediastinum.<sup>10</sup>

## CONCLUSION

Giant mediastinal thyroid is rare and can be associated with or without connection to anatomical thyroid enlargement. Plunging retrosternal thyroid as posterior mediastinal mass is much more unusual to see. It should be considered in mediastinal mass evaluation and also to be differentiated, substernal goiter from other mediastinal mass.

Surgical excision is gold standard treatment and approach is varied depends on location of gland. The extended cervical incision or partial sternotomy is adequate for

small sub sternal goiter but the extended total sternotomy needed for giant total mediastinal plunging thyroid mass.

*Funding: No funding sources*

*Conflict of interest: None declared*

*Ethical approval: Not required*

## REFERENCES

1. Regal MAH, Zakaria HM, Ahmed AS, Aljehani YM. Substernal Thyroid Masses. *Oman Med J.* 2010;25(4):315-7.
2. Shields TW. *Mediastinal Thyroid Tumors.* Thoracic Surgery., New York, Edinburgh, London, Philadelphia: Churchill Livingstone Press; 2002: 1748-1759.
3. Xu J, Shen B, Li Y, Zhang T. Enormous goiter in posterior mediastinum: report of 2 cases and literature review. *J Formos Med Assoc.* 2009;108(4):337-43.
4. Fragomeni LS, Ceratti de Azambuja P. Intrathoracic goitre in the posterior mediastinum. *Thorax.* 1980;35(8):638-9.
5. Regal M, Kamel MM, Alyami H, AL-Osail EM. Mediastinal ectopic thyroid mass with normal thyroid function and location: Case report. *Int J Surg Case Rep.* 2018;52:5-7.
6. Fuhrer D, Bockisch A, Schmid. Euthyroid Goiter With and Without Nodules—Diagnosis and Treatment. *Dtsch Arztebl Int.* 2012;109(29-30):506-16.
7. Roh E, Hong ES, Ahn HY, Park SY, Yoon HI, Park KS, et al. A case of mediastinal ectopic thyroid presenting with a paratracheal mass. *Korean.* 2013;28(3):361-4.
8. Scognamiglio F, Attene F, Paliogiannis P, Ruggiu MW, Cossu A, Trignano M. Is sternotomy always necessary for the treatment of mediastinal ectopic thyroid goiter? *Ann Ital Chir.* 2014;85(3):304-7.
9. Di Crescenzo V, Vitale M, Valvano L, Napolitano F, Vatrella A, Zeppa P, et al. Surgical management of cervico-mediastinalgoiters: Our experience and review of the literature. *Int J Surg.* 2016;28(1):47-53.
10. de Perrot M, Fadel E, Mercier O, Farhamand P, Fabre D, Mussot S, et al. Surgical management of mediastinal goiters: when is a sternotomy required? *Thorac Cardiovascular Surg.* 2007;55(1):39-43.

**Cite this article as:** Punjani JN, Shah KK, Haridas AK. Giant retrosternal goiter masquerading as, right posterior mediastinal mass: a rare case report. *Int Surg J* 2020;7:306-9.