

## Original Research Article

# Acid corrosive injury of stomach: management and long-term outcome

Mohit Sharma\*, Rachhpal Singh

Department of Surgery, Sri Guru Ram Das Institute of Medical Sciences and Research, Vallah, Amritsar, Punjab, India

**Received:** 14 July 2020

**Revised:** 30 July 2020

**Accepted:** 31 July 2020

**\*Correspondence:**

Dr. Mohit Sharma,

E-mail: [drmohit.gis@gmail.com](mailto:drmohit.gis@gmail.com)

**Copyright:** © the author(s), publisher and licensee Medip Academy. This is an open-access article distributed under the terms of the Creative Commons Attribution Non-Commercial License, which permits unrestricted non-commercial use, distribution, and reproduction in any medium, provided the original work is properly cited.

### ABSTRACT

**Background:** Acid corrosive injury to stomach is not uncommon in India due to easy availability. Corrosive ingestion results in significant morbidity. We present our experience in surgical management of such cases. The aims and objectives of this study to review the experience of surgical management of gastric corrosive injury and to assess long term outcome and functional results.

**Methods:** This study was retrospective analysis of prospectively collected data of 23 cases of acid corrosive injury managed in a single surgical unit.

**Results:** Median age was 31 years, male to female ratio was 12:11. Surgical procedures were tailored according to extent and degree of stricture. Posterior gastrojejunostomy was done in 8 (38.0%) cases, near total gastrectomy in 3 (14.3%) cases, total gastrectomy and Billroth I in 2 (9.5%) cases each. 4 cases were lost to follow up after preliminary feeding jejunostomy. 2 cases had mortality after feeding jejunostomy. 2 cases were managed successfully without active surgical intervention. All patients undergoing definitive procedure had good results in terms of nutritional status and symptoms of gastric outlet obstruction.

**Conclusions:** The outcome of gastric stricture secondary to acid ingestion can be significantly improved by adequate preoperative preparation and planned approach depending upon type of injury.

**Keywords:** Corrosive ingestion, Gastric stricture, Gastric outlet obstruction, Gastrectomy

### INTRODUCTION

Corrosive ingestion whether accidental or suicidal remain a significant problem in our society. Lack of legal regulations, easy accessibility and unrestricted sale of acid is the main contributor of the acid poisoning cases.<sup>1</sup> Unlike alkali which is viscous and tend to adhere to esophageal mucosa, acid rapidly transcends esophagus, induces pyloric spasm, this results in greater duration of contact with gastric mucosa, coagulative necrosis and gastric stricture.<sup>2</sup> Presenting features depend upon the timing of presentation and ranges from acute emergency to later stage with sequel of pyloric antrum stricture. In this article we report our experience in surgical

management of gastric corrosive injury and its long-term outcome.

The objective was to review the experience of surgical management of gastric corrosive injury. The secondary objective was to assess long term outcome and functional results.

### METHODS

This study was retrospective analysis of prospectively collected data of patients admitted with corrosive acid ingestion in a single surgical unit of Sri Guru Ram Das Institute of Medical Sciences and Research, Vallah, Amritsar from June 2010 to June 2020.

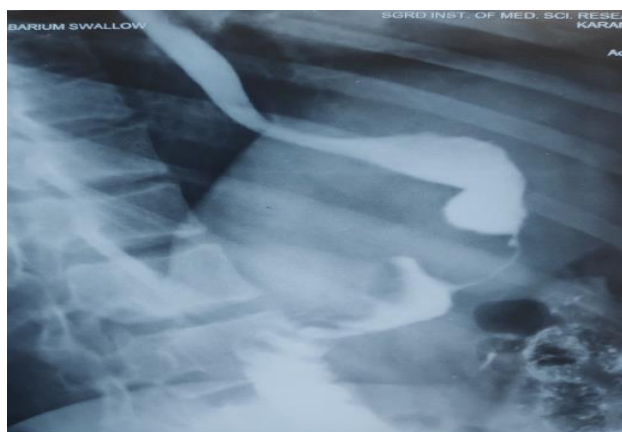**Inclusion criteria**

Inclusion criteria were patients with isolated or predominant acid corrosive injury to stomach.

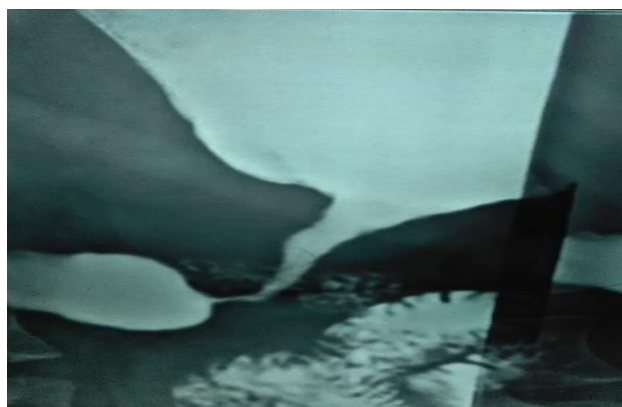
**Exclusion criteria**

Exclusion criteria were patients with predominant esophageal strictures.

Details of the records of patient with isolated gastric or predominant gastric injury were reviewed with attention to presenting features, interval between time of ingestion and presentation to hospital, etiology of ingestion, management done, immediate and long-term outcome.



**Figure 1: Diffuse gastric stricture.**



**Figure 2: Distal gastric stricture.**

Statistical analysis was done using SPSS 20.0 version.

**RESULTS**

From June 2010 to June 2020, 23 patients were admitted in a single surgical unit of a tertiary care hospital (Table 1). 19 (82.6%) patients presented in emergency with history of acute ingestion, 4 (17.39%) patients presented in outdoor with symptoms of gastric outlet obstruction. Median age of presentation was 31 (range 20-55 years). Male to female ration was 12:11. Corrosive ingestion was

suicidal in 17 (73.9%) and accidental in 6 (26.08%) cases. 3 patients were known case of depression and were already under treatment with psychiatrist. Our management of acute corrosive injury is usually focused on initial resuscitation, assessing severity of injury, treating early complications if any, maintenance of nutrition and treatment of stricture. Our policy is to do early endoscopy within 3 to 5 days of corrosive ingestion. 2 (8.69%) cases had grade I injury (Zargar’s classification), they were started on early liquid diet and were discharged subsequently without any adverse consequences.<sup>3</sup> In cases of grade IIIa injury and above we go for feeding jejunostomy for early start of enteral nutrition. Preliminary feeding jejunostomy was done in 17 cases (73.91%). 4 cases presenting with symptoms of gastric outlet obstruction were managed with definitive procedure without preliminary feeding jejunostomy. Two patients undergoing feeding jejunostomy died without undergoing definitive procedure. One died within eight days of severe pneumonia, respiratory failure and sepsis, she had concomitant acid aspiration injury to pulmonary symptoms. Another died a month later of severe malnutrition and septicaemia despite being on jejunostomy feeds. 4 patients were lost to follow up without undergoing definitive procedure. Mean interval from date of ingestion to definitive surgery was 130.7 days. The choice of definitive surgery for gastric outlet obstruction was determined by extent of cicatrisation of the stomach (Figure 1 and 2). 3 (14.3%) patients had associated esophageal stricture managed successfully with serial esophageal dilatation. In patients with stricture involving entire stomach, Total gastrectomy was done in 2 (9.5%) cases. Near total gastrectomy with Roux-en-Y gastrojejunostomy was done in 3 (14.3%) patients, these cases have stricture involving body and distal stomach. Patients having limited stricture involving pylorus were dealt with Billroth I in 2 (9.5%) cases. Posterior gastrojejunostomy was done in 8 (38.0%) patients (Table 2).

**Table 1: Detail of cases.**

Patient characteristics	n=23
Median age in years (range)	31 (20-55)
Male	12
Female	11
Corrosive agent	Toilet cleaner (acid)
Etiology N (%)	
Accidental	6 (26.08)
Suicidal	17 (73.91)
Presentation N (%)	
Emergency	19 (82.6)
Elective	4 (17.39)
Preliminary feeding jejunostomy	17 (73.91)
Mean interval between ingestion and definitive surgery (in days)	130.7
Mean follow up (in months)	44.15

**Table 2: Details of definitive procedure.**

Procedure	N (%)
Posterior gastrojejunostomy	8 (38.0)
Total gastrectomy	2 (9.5)
Near total gastrectomy	3 (14.3)
Billroth I	2 (9.5)
Total	15

**Table 3: Morbidity and mortality.**

Variables	Short term	Long term
<b>Morbidity</b>	Surgical site infection n=2 (9.5%)	Incisional hernia n=2 (9.5%) 9 and 13 months respectively
<b>Mortality</b>	n=1 (4.76%) POD- 8 Respiratory failure	n=1 (4.76%) severe malnutrition 1 month after FJ

2 (9.5%) patients had surgical site infection. 1 (4.76%) patient had mortality on postoperative day 8 after preliminary feeding jejunostomy secondary to respiratory failure and septicaemia. Mean follow up was 44.15 months. 1 (4.76%) case had mortality a month after preliminary feeding jejunostomy secondary to severe malnutrition. 2 (9.5%) patients developed incisional hernia 9 and 13 months respectively, after definitive procedure and required mesh hernioplasty. All patients showed good outcomes in term of weight gain and remained asymptomatic in terms of symptoms of gastric outlet obstruction (Table 3).

## DISCUSSION

Corrosive injury to upper gastrointestinal tract is not uncommon cause of hospitalization in India. Relatively easy availability and unrestricted sale of acid as toilet cleaning agent contributes to the incidence of both accidental and suicidal cause of acid injury to esophagus and stomach.<sup>4</sup> Stricture following corrosive ingestion is an important late complication. It usually starts within 2-3 weeks and progress rapidly.<sup>5</sup> Injury to stomach as a consequences of acid ingestion usually occur along lesser curvature and prepyloric region. Prepyloric and antrum is the commonest site owing to reflex pylorospasm and pooling of secretions in this region.<sup>6</sup> The resulting fibrosis and stricture causes gastric outlet obstruction. Site and severity of stricture in the upper gastrointestinal tract depend upon multiple factors like nature and concentration of agent, intent of ingestion (suicidal or accidental), fasting or fed state.<sup>7</sup> In our series we have included patients with isolated or predominant gastric stricture, associated esophageal stricture were present in 3 of our cases 14.3%. In these cases, esophageal strictures were easily managed by serial dilatations. Kamijo and Feng et al has reported concomitant esophageal and gastric stricture in 6 to 63% of cases.<sup>8,9</sup> Common

symptoms at presentation are persistent vomiting and weight loss. Majority of patients present between 1 to 3 months although delayed presentation has also been reported.<sup>10</sup>

Upper GI endoscopy and barium study are important tool to understand the extent and severity of injury. Ananthakrishnan et al has classified gastric stricture into five types.<sup>1</sup>

- *Type I:* Short ring stricture within 1 to 2 cm of the pylorus.
- *Type II:* Stricture extending proximally upto the antrum.
- *Type III:* Mid gastric stricture involving the body sparing the proximal and distal aspect of stomach.
- *Type IV:* Diffuse gastric involvement like the linitis plastica.
- *Type V:* Gastric stricture associated with the first part of duodenum.

In our study 2 (9.52%) patients had type I, 8 (38.0%) cases type II, 3 (14.2%) cases type III, 2 (9.52%) cases of type IV and there was no patient with type V stricture.

Definitive surgery is usually recommended 3 to 24 months after date of ingestion.<sup>11,12</sup> We also follow the policy of minimum waiting period of 90 days before performing definitive surgery. In our series mean interval was 130.7 days from the date of ingestion to definitive surgery. Enteral nutrition in the interval period was maintained with the help of feeding jejunostomy. However, one of our patients became severely malnourished despite being on jejunostomy feeds, she succumbed to severe malnutrition and septicaemia. Early definitive surgery was reported by some authors, Tseng et al within 2 months, Hwang et al within 1 to 4 months.<sup>13,14</sup> These authors reported that early definitive surgery can give better quality of life without any mortality or significant morbidity. Surgery in corrosive stricture is tailored according to extent and pattern of gastric involvement. Re-sectional surgery in our case series ranges from total gastrectomy 2 (9.5%) cases, near total gastrectomy 3 (14.3%) cases to Billroth I procedure 2 (9.5%) cases. Many surgical centers perform some form of gastric resection considering the possibility of malignancy in scarred stomach.<sup>15</sup> In comparison to reports of future malignancy developing in corrosive esophageal stricture, there are no significant reports of malignancy in gastric corrosive stricture.<sup>16</sup> Hsu et al experienced no case of malignancy arising from background of corrosive ingestion on examination of more than 2000 gastric cancers.<sup>17</sup> In comparison to gastric resection gastrojejunostomy is lesser procedure and reasonable alternative particularly in difficult to construct Billroth I due to significant luminal disparity. In our series we considered posterior gastrojejunostomy as alternative to Billroth I in 8 (38.0%) patients. All the patients were maintained on regular follow up. The mean follows up period was 44.15 months. All patients showed

significant improvement in terms of symptoms and nutritional status.

## CONCLUSION

Acid corrosive ingestion results in significant morbidity. Two staged procedure is required to manage such patients feeding jejunostomy initially to maintain enteral nutrition and definitive surgery at an interval. Surgery is tailored according to extent and pattern of involvement. The outcome of corrosive acid induced stricture can be significantly improved by adequate preoperative preparation and planned approach depending upon type of injury.

*Funding: No funding sources*

*Conflict of interest: None declared*

*Ethical approval: Not required*

## REFERENCES

1. Ananthkrishnan N, Parthasarthy G, Kate V. Chronic corrosive injuries of the stomach- a single unit experience of 109 patients over thirty years. *World J Surg.* 2010;34:758-64.
2. Ramasamy K, Gumaste VV. Corrosive ingestion in adults. *J Clin Gastroenterol.* 2003;37:119-24.
3. Zargar SA, Kochhar R, Nagi B. Ingestion of corrosive acids. Spectrum of injury to upper gastrointestinal tract and natural history. *Gastroenterology.* 1989;97:7020707.
4. Ananthkrishnan N, Parthasarthy G, Kate V. Acute corrosive injuries of the stomach: A single unit experience of thirty years. *ISRN Gastroenterol.* 2011;2011:914013.
5. Kalayarasan R, Ananthkrishnan N, Kate V. Corrosive ingestion. *Indian J Crit Care Med.* 2019;23:282-6.
6. Tohda G, Sugawa C, Gayer C, Chino A, Guire TW, Lucas CE. Clinical evaluation and management of caustic injury in upper gastrointestinal tract in 95 adult patients in urban medical centre. *Surg Endosc.* 2008;22:1119-25.
7. McAuley CE, Steed DL, Webster MW. Late sequelae of gastric acid injury. *American J Surg.* 1985;149:412-5.
8. Kamijo Y, Kondo I, Watanebe M, Kano T, Ide A, Soma K. Gastric stenosis in severe corrosive gastritis, prognostic evaluation by endoscopic ultrasonography. *Clinical Toxicology (Phila).* 2007;45:284-6.
9. Feng J, Gu W, Li M, Yuan J, Weng Y, Wei M, et al. Rare cause of gastric outlet obstruction in children. *Pediatric Surg Int.* 2005;21:635-40.
10. Agarwal S, Sikora SS, Kumar A, Saxena R, Kapoor VK. Surgical management of corrosive stricture of stomach. *Indian J Gastroenterol.* 2004;23:178-80.
11. Chaudhary A, Puri AS, Dhar P, Reddy P, Sachdeva A, Lahoti D, et al. Elective surgery for corrosive induced gastric injury. *World J Surg.* 1996;20:703-6.
12. Chung PH, Chih YC, Nan YH, Jiun YH. Surgical treatment and its long-term results for caustic induced prepyloric obstruction. *Eur J Surg.* 1997;163:275-9.
13. Tseng YL, Wu MH, Lin MY, Lai WW. Early surgical correction for isolated gastric stricture following acid corrosion injury. *Dig Surg.* 2002;19(4):276-80.
14. Hwang TL, Chen MF. Surgical treatment of gastric outlet obstruction after corrosive injury can early definitive operation be used instead off staged operation. *Int Surg.* 1996;81:119-21.
15. Zamir O, Hod G, Lernau OZ, Mogle P, Nissan S. Corrosive injury to the stomach due to acid ingestion. *Am J Surg.* 1985;51:170-2.
16. Ti TK. Oesophageal carcinoma associated with corrosive injury-prevention and treatment by oesophageal resection. *Br J Surg.* 1983;70(4):223-5.
17. Hsu C, Chen C, Hsu N, Hsia J. Surgical treatment and its long-term result for caustic induced prepyloric obstruction. *Eur J Surg.* 1997;163:275-9.

**Cite this article as:** Sharma M, Singh R. Acid corrosive injury of stomach: management and long-term outcome. *Int Surg J* 2020;7:2875-8.