

## Case Report

# Abdominal perineal resection surgery: case report

Haitham A. Saimeh\*

Department of Medicine, King Faisal Hospital and Research Centre, Jeddah, Saudi Arabia

**Received:** 25 July 2020

**Revised:** 19 August 2020

**Accepted:** 21 August 2020

**\*Correspondence:**

Dr. Haitham A. Saimeh,

E-mail: [haithamsaimeh@yahoo.com](mailto:haithamsaimeh@yahoo.com)

**Copyright:** © the author(s), publisher and licensee Medip Academy. This is an open-access article distributed under the terms of the Creative Commons Attribution Non-Commercial License, which permits unrestricted non-commercial use, distribution, and reproduction in any medium, provided the original work is properly cited.

### ABSTRACT

Colorectal cancer is known to be the most diagnosed cancer in the world, the set gold standard for the treatment of colorectal cancer is excision of the tumor via surgery. There is different type of surgeries that tend to be performed depending on the location, size and extent of the mass in order to avoid recurrence. The main aim of this paper is to discuss the abdominal perineal resection surgery together with the complications faced and criteria in managing these complications intraoperatively.

**Keywords:** Abdominal perineal resection surgery, Effective packing and second look, Colorectal cancer

### INTRODUCTION

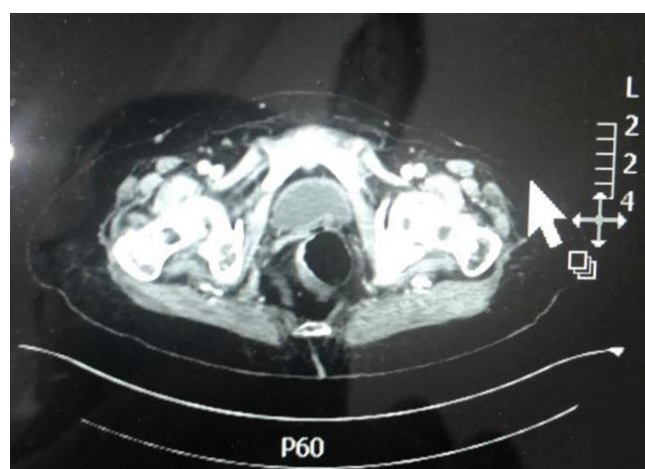
Based on the data collected by the World Cancer Research Fund, colorectal cancer is the third most commonly occurring cancer in men and the second most commonly occurring in women. Surgical removal of rectal cancer is considered to be the gold standard in the treatment of rectal cancer, however the type of surgical procedure followed in order to excise the tumor mainly depends on the precise location and extent of the tumor. APR is a surgery in which the rectum, distal colon, and anus are removed which leads to a permanent colostomy and it is considered to be a standard surgical procedure when the tumor is located close to the anus.

The aim of this study is to ensure the importance of doing abdominoperineal resection for surgical removal of a mass and method of managing bleeding intraoperatively.

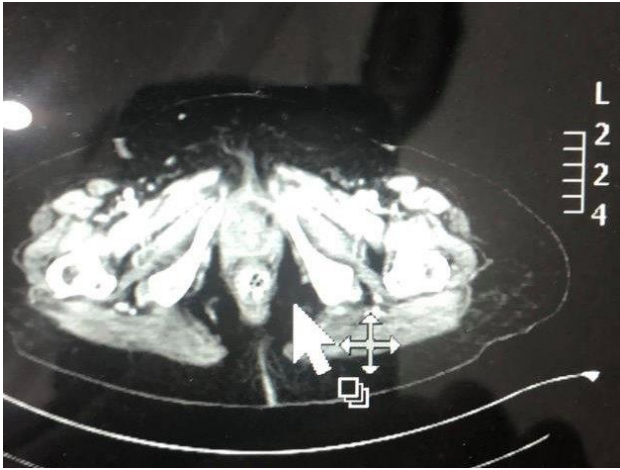
### CASE REPORT

A 72 years old female patient already diagnosed with rectal cancer 5 cm from the anal verge. After full pelvic magnetic resonance imaging (MRI), abdominal, pelvic and chest computed tomography (CT) scan investigations, the case

was discussed with the tumor board committee, the decision was to go for abdominoperineal resection (APR) but the procedure was complicated by presacral plexus and the decision was to do packing over the bleeding in the pelvic area and to bring after 48 hours for a second look (Figure 1 and 2).



**Figure 1: Pelvic MRI indicating the presence of rectal tumor.**



**Figure 2: CT scan showing the rectangular mass.**

The patient is not diabetic, hypertensive, and had no other underlying comorbidities. She was seen and examined by the anaesthetist before the operation, then she was declared fit for the surgery. Haemoglobin level was (109 g/L), liver and kidney function test together the coagulation profile were all normal. International normal ratio (I.N.R) was 1.1 ratio, which is in the normal range.

Preoperative diagnosis of the patient is presacral plexus post abdominoperineal resection with packing over the bleeding, operation performed was laparotomy and second look operation and removal packs. Estimated blood loss was 20 ml, but no major complications were encountered. One drain was needed.

Under general anaesthesia with the patient in modified lithotomy position, cleaning and towelling done. A middle was made 2 cm above the umbilicus and till symphysis pubis down, lower middle incision, opening by layers till we entered the abdomen. Then, repositioning was done, head down and right-side shift. Then, taking the small bowel segment by using wet gauze from the pelvic area and then insertion of self-retaining retractor. Then, we started dissection from sigmoid colon starting laterally from the Toldt line. Using the cautery, complete dissection was done laterally till reached splenic flexure. We freed lateral edge. The, starting from the medial edge using LigaSure cutting and ligation of the pedicle then going down to rectosigmoid area to the rectum. We started dissection of mesorectal area. During dissection and identification of the whole plane, there was bleeding in the presacral plexus and using 4-0 prolene suture it was controlled and Tachosil was put over this presacral plexus bleeding. We continued dissection from the abdomen, total mesorectal excision was done from lateral, medial side and anterior till we reached the upper vaginal lip. After that, haemostasis was secured for this presacral plexus using LigaSure and Tachosil. We went down to the perineal area and started dissection there. An elliptical incision was made around the anus after ligation of the anus. After that, pull through the ischioanal fossa till the sacral promontory. Then, complete excision was done and

pushing the mass from the abdomen till the pelvis. Haemostasis was secured down and suturing of the muscle using 3-0 vicryl and then insertion of a drain. Attention was directed to the abdominal area, there was presacral plexus bleeding. We tried to control it by TachoSil and ligation, but failed, still continuous bleeding. The decision was to call for vascular surgeon assistance, he made suture, but it was difficult to take the suture because it was over the sacral bone. After trying all the trials for haemostasis, the decision was to go for packing the area and for a second look after 48 hours, packing was done by inserting four abdominal gauze. Creation of colostomy was done in the left upper quadrant using 4-0 vicryl and all suture around the colostomy area and skin.

Closure of the abdomen was done by using looped polydioxanone (PDS) and putting one drain in the left side and to take the patient after 48 hours for a second look.

The patient received two units of packed red blood cells intraoperative and then was transferred to the intraoperative care unit on the same day of the operation. Haemoglobin dropped to (81 g/L), another three units of packed red blood cells were given together with two units of fresh frozen plasma. Intra-abdominal drain was inserted to avoid fluid collection and when observed, it was bringing 260 cubic centimetre (cc) serous fluid blood in the first day and the perineal drain was bringing 130 cc serous blood. There are no enough prove that intra-abdominal drain protects from anastomotic leakage, yet it prevents the development pelvic collections.<sup>5</sup>

Haemoglobin level improved on the first day post-operatively to (98 g/l), the patient was incubated, fully sedated with stable vital signs, blood pressure was in the range of 130/80 mmHg in the intensive care unit (ICU), pulse was within the range of 85 to 95 beats per minute. In the second day postoperatively, haemoglobin level dropped to (87 g/l), then another two units of packed red blood cells together with two units of fresh frozen plasma was transferred. Coagulation tests were in the normal range, I.N.R 1.1 ratio.

After 48 hours, the patient was taken back to the operating room again for the second look, packs were removed, and bleeding was absent.

The patient was observed clinically, she has stable vital signs, Blood pressure 120/80 mph, pulse 85 beats per minute, haemoglobin level (110 g/l). Intra-abdominal and perineal drainage with little amount of serous fluid, was removed. The patient was discharged in a good condition.

## DISCUSSION

Abdominoperineal resection is considered to be a challenging surgical procedure, in which this procedure is considered to have poorer oncological outcome due to several reasons, in which a capable well experienced surgeon may fail to achieve total clear circumferential

resection margin, as well as increase the risk of intraoperative perforations, in return this greatly increase the chance of local recurrence.<sup>1</sup> In the present case, the patient had no underlying comorbidities, therefore this reduces the chance of delayed perineal wound healing which is considered the most frequent complication encountered, based on previous recorded literature, wound dehiscence and infection incidence ranges from 10 to 40 %.<sup>2</sup>

Intraoperative hemorrhage is a common complication of colorectal surgery, therefore surgeons should try to avoid it by maintaining good teamwork and qualified operational and management skills.<sup>3</sup>

During the operation, mobilizing and dissecting the rectosigmoid junction in the total meso-rectal excision, severe bleeding occurred in the pelvic area, at the area of the holey plan, without vessels, clean and safe to dissect the mesorectum down to the pelvic brim. Bleeding was controlled by packing and stitching the vessels. Effective packing is lifesaving by reducing the chance of encountering recurrent bleeding episodes, however it may increase the risk of encountering an infection because it provides an environment for implantation of foreign material that increases the risk of pelvic sepsis.<sup>4</sup> Further continuing the dissection downward and after perineal resection down from the anal area and removing all the specimen with the tumor, bleeding restarted in the pelvic area, specifically in the presacral plexus vessels, trials to control and minimize the bleeding by stitching or by applying anticoagulants material over the bleeding plexus vessels failed to stop the bleeding. Vascular surgeon intervention was highly needed, vascular surgery team tired their best to stop and control the bleeding also by using suturing but still bleeding continued massively therefore it was decided to do effective packing in the pelvic area by applying pressure abdominal gauze and tacocyle materials, together with coagulants material for 48 hours duration, then to have a second look by re-operation.

According to conducted studies, wound infection, dehiscence, abscess and delayed healing tend to be the major post-operative complications because of the complex positioning requirements of the patient as well as the length of the operation. To avoid cardiac and pulmonary complications, the patient was given preoperatively beta blockers as a prophylactic measurement to avoid deep vein thrombosis (DVT).<sup>8</sup> In our case, no cardiac or pulmonary complications were encountered, yet these complications account for 3% of total abdominoperineal resection (APR) complications.

Regardless of the great advances in surgical intervention, yet perineal wound infection remains a major threat to surgeons especially when a pelvic drainage is inserted as in this discussed case, since pelvic drainage leads to increased postoperative morbidity rates since it prolongs wound healing.<sup>9</sup> Perineal drainage complications greatly

affects the quality of life the patients experience, in this discussed case no complications were encountered because constant care was done together with the fact that the patient had no other underlying comorbidities as diabetes, hypertension, and obesity. Based on a previous conducted study, obesity increases wound complications by 10%.<sup>10</sup>

## CONCLUSION

The main indication of APR is when rectal carcinoma is situated in the lower one third of the rectum, however the most encountered complication include haemorrhage, and perineal wound complications.

Effective packing is lifesaving by reducing the chance of encountering recurrent bleeding episodes, therefore packing technique should always be a practiced skill together with suturing in order to achieve patient wellbeing and avoid any unstable hemodynamic profile.<sup>6,7</sup>

Wound packing and second look are a safe method to control the bleeding in the pelvic region for the presence of plexus bleeding, and early control of the bleeding together with making DIC (disseminated intravascular coagulation) which may result in losing the patient life. We should always choose the safest and best way to control bleeding in the pelvic region.

*Funding: No funding sources*

*Conflict of interest: None declared*

*Ethical approval: Not required*

## REFERENCES

1. Feeney G, Sehgal R, Sheehan M, Hogan A, Regan M, Joyce M, Kerin M. Neoadjuvant radiotherapy for rectal cancer management. *World J Gastroenterol.* 2019;25:4850-69.
2. Aarons CB, Mahmoud NN. Current surgical considerations for colorectal cancer. *Chin Clin Oncol.* 2013;2(2):14.
3. Zhang L, Junjun M, Zang L, Dong F, Lu A, Feng B, He Z, Hong H, Zheng M. Prevention and management of hemorrhage during a laparoscopic colorectal surgery. *Ann Laparoscopic Endoscopic Surg.* 2016;1(7).
4. Celentano V, Ausobsky JR, Vowden P. Surgical management of presacral bleeding. *Ann R Coll Surg Engl.* 2014;96:261-5.
5. Puleo FJ, Mishra N, Hall JF. Use of intra-abdominal drains. *Clin Colon Rectal Surg.* 2013;26:174-7.
6. Celentano V, Ausobsky JR, Vowden P. Surgical management of presacral bleeding. *Ann R Coll Surg Engl.* 2014;96:261-5.
7. Zama N, Fazio VW, Jagelman DG, Lavery IC, Weakley FL, Church JM. Efficacy of pelvic packing in maintaining hemostasis after rectal excision for cancer. *Dis Colon Rectum.* 1988;31(12):923-8.

8. Perry WB, Connaughton JC. Abdominoperineal resection: how is it done and what are the results? *Clin Colon Rectal Surg.* 2007;20(3):213-20.
9. Pramateftakis MG, Raptis D, Kanellos D, Christoforidis E, Tsoulfas G, Kanellos I, Lazaridis C. Abdominoperineal resection for rectal cancer: is the pelvic drain externalization site an independent risk factor for perineal wound healing? *Int J Surg Oncol.* 2012;156935.
10. Blake P. Drain pain, overflow, and how they are connected. *Peritoneal Dialysis Int.* 2014;34(4):342-4.

**Cite this article as:** Saimeh HA. Abdominal perineal resection surgery: case report. *Int Surg J* 2020;7(9):3105-8.