

Case Report

Emergency surgery amid ongoing pandemic in suspected COVID-19 with D1 perforation

Mrinal Shankar*, Manoj Kumar Chaudhary, Shubham Samal, Radhakrishna Ramchandani

Department of General Surgery, All India Institute of Medical Sciences, Raipur, Chhattisgarh, India

Received: 01 August 2020

Accepted: 14 August 2020

*Correspondence:

Dr. Mrinal Shankar,

E-mail: ms_surg@yahoo.co.in

Copyright: © the author(s), publisher and licensee Medip Academy. This is an open-access article distributed under the terms of the Creative Commons Attribution Non-Commercial License, which permits unrestricted non-commercial use, distribution, and reproduction in any medium, provided the original work is properly cited.

ABSTRACT

The COVID-19 pandemic has affected working patterns of all emergency and regular surgical services. We report a case of emergency surgery amid this ongoing pandemic, in a suspected COVID-19 patient with D1 (duodenal) perforation. We did not wait for the real time polymerase chain reaction (RT-PCR) report for severe acute respiratory syndrome coronavirus 2 (SARS-CoV-2) to come, and proceeded with surgery with all safety protocols. We intend not to delay, for the better outcome of patient's condition, the life-saving response alike we follow routinely. The pandemic scenario is expected to sustain for longer time. We assume, patients requiring acute care surgery with COVID-19 like symptoms (suspected or confirmed), should definitely be proceeded with surgery as earliest, following all safety protocols, and prevent undue and added morbidity and mortality during this pandemic crisis.

Keywords: COVID-19 pandemic, Real time polymerase chain reaction for SARS-CoV-2, Emergency surgery, Perforation, Safety protocols, Personal protective equipment

INTRODUCTION

The worldwide pandemic of COVID-19 has shifted working patterns in all aspect of patient care either elective or acute care services. Majority of elective surgeries has been postponed in worst affected areas. The challenge arise in patients requiring acute care surgery. Cases like acute abdomen or fatal blunt trauma abdomen always require emergency surgical intervention. During current pandemic crisis, we have to screen and assess all these patients for COVID-like symptoms also, if they present from a defined containment zone of current pandemic. Waiting for real time polymerase chain reaction (RT-PCR) report for severe acute respiratory syndrome coronavirus 2 (SARS-CoV-2) will be injustice in patient care in patients requiring emergency surgery. With all adequate safety protocol measures, personal protective equipment (PPE) support and minimum manpower involvement we must proceed to deliver all acute care services without delay. Consider these patients as suspected COVID, unless

proven negative with RT-PCR. We share our pandemic experience of emergency surgery in a suspected COVID-19 patient with D1 (duodenal) perforation.^{1,2}

CASE REPORT

A 48 year female presented in emergency with chief presenting complain of gradually progressive pain in abdomen for past 1 day, more confined in upper abdomen. It was associated with 2 episodes of non-bilious vomiting, not passed flatus and stool for 1 day. The alarming associated symptoms amid COVID-19 pandemic was of persistent productive cough for past 1 week with history of on and off low to intermediate grade fever during the same period. Also, the patient came from a containment zone (red zone), with highest cases of COVID-19 being revealed from the said locality, at that moment. Patient attendants were migrant labour returnee from COVID hotspot metropolitan. The patient otherwise had no recognised co-morbid condition.

On clinical examination, radial pulse was 104/min regular, blood pressure (BP) 120/86 mmHg and low grade fever. Saturation of peripheral oxygen (SpO₂) 84-88% with 4 litres of oxygen. Basal crepts on auscultation of chest. Abdomen was distended, tense with diffuse tenderness confined in upper abdomen. Guarding and rigidity were not appreciated in this patient as we routinely interpret in cases of perforation peritonitis.

X-ray chest erect was done, which showed gas under both domes of diaphragm, establishing our diagnosis of perforation peritonitis.

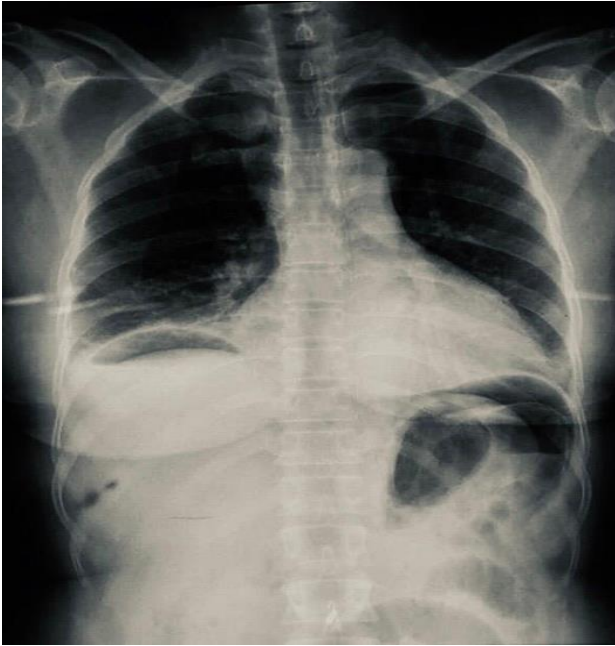


Figure 1: X-ray chest erect showing gas under both domes of diaphragm, establishing our diagnosis of perforation peritonitis.

Arterial-blood gas (ABG) suggested primary metabolic acidosis compensated by respiratory alkalosis. Routine blood investigations were sent [Hemoglobin concentration (Hb) 10.8 g/dl, total leucocyte count (TLC) 15500/mm³, creatinine 0.9 mg/dl, sodium (Na⁺) 135 mmol/l, potassium (K⁺) 4.52 mmol/l, total bilirubin 1.88 mg/dl].

Patient was undertaken for emergency exploratory laparotomy. We intend to keep minimum manpower in operation theatre (OT) in times of COVID-19. Adequate full coverall PPE were used by all involved in OT including anaesthesia team, nursing staff, primary surgeon and the assistant. Under general anaesthesia, midline abdominal incision was taken. Approximately 1 litre of bilio-purulent contamination were drained. Thorough lavage with warm saline was given. A 1×1 cm D1 perforation was repaired with modified Graham's patch repair technique. Drains were placed. RT-PCR for SARS-CoV2 were sent from nasal, throat and abdominal contamination.

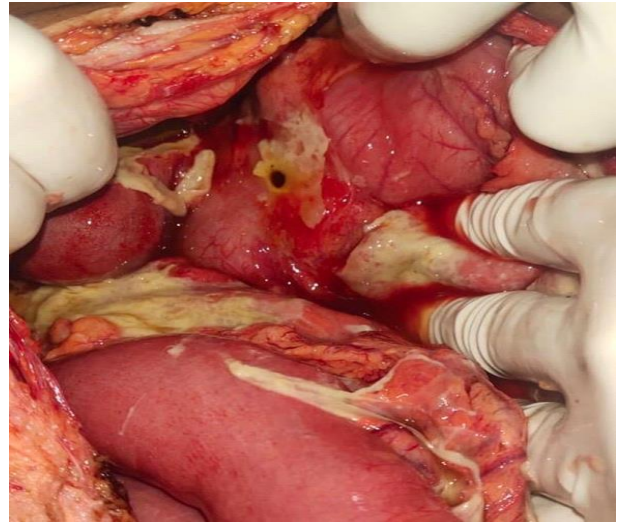


Figure 2: 1×1 cm D1 perforation.

The patient was extubated and shifted directly towards the isolation side of surgery ward, with all necessary measures in preparation considering COVID suspect. The team involved in surgery were advised isolation in their home/room till the COVID report of patient was ascertained. The RT-PCR report came negative next day. The patient had faster recovery in post-operative course, was allowed orally from 4th day, drains were removed by 6th day and was discharged subsequently after 7 days of surgery with stable haemodynamic condition.

DISCUSSION

The indications for emergency surgery are the same. COVID-19 pandemic has just shifted the working pattern. In suspected COVID patients, proceeding with emergency surgery has become a major challenge for the surgical team. Waiting for RT-PCR confirmation is injustice in acute patient care, as testing takes prolonged duration to ascertain us the COVID-19 status of patient. More to it, the virology laboratories at current scenario are loaded with samples to give any undue priority to all emergency surgery cases.

Previously also, the surgeons regularly operate in emergency, the cases of acute abdomen with poor chest or pneumonia like symptoms. But the COVID pandemic has added difficulty in differentiating any associated respiratory symptoms to be not associated with SARS-CoV-2. Although our intend is not to delay treatment, and thus it is important to adopt new work pattern with adequate safety protocol norms to be followed in general. The highest level of protection, minimum team exposure and proper coordination is must. A separate team in patient care should be deployed here.^{3,4}

The team scrubbed in emergency surgery of suspected COVID patients should have access to all components of PPE to ascertain the highest of safety. Minimum

manpower should be preferred to the best of possibility. The aerosol generation should be limited.

Laparoscopic surgeries need added care due to establishing and removing of pneumoperitoneum, or any air leakage from trocar sites. Thus, conventional open surgeries has regained preference in this pandemic, owing to lesser time duration, and comfort levels.

Performing surgery with full coverall PPE is not an easy task, as no one is routinely acclimatized with this pattern of doing operations. It adds to difficulty in various steps, fogging over glasses/eyes are another challenging circumstances at the moment.⁵

In suspected COVID patients with associated co-morbid conditions, a rigorous post-operative care is being required to prevent flaring of morbidity and mortality.

It is early to say, as no major study or general consensus has been seen in accessing virus load in abdominal contamination of patients with perforation peritonitis. Abdominal contamination should also be sent for RT-PCR test to access any SARS-CoV-2 load.

CONCLUSION

We assume, patients requiring acute care surgery with COVID-19 like symptoms (suspected or confirmed), should definitely be proceeded with surgery as earliest, following all safety protocols, and prevent undue and added morbidity and mortality during this pandemic crisis.

Funding: No funding sources

Conflict of interest: None declared

Ethical approval: Not required

REFERENCES

1. Gao Y, Xi H, Chen L. Emergency surgery in suspected COVID-19 patients with acute abdomen: case series and perspectives. *Ann Surg.* 2020;272(1):38-9.
2. He L, Zhao W, Zhou W, Pang P, Liao Y, Liu J. an emergency surgery in severe case infected by COVID-19 with perforated duodenal bulb ulcer. *Ann Surg.* 2020;272(1):35-7.
3. Kühn F, Klein M, Laven H, Börner N, Weinberger T, Streitparth F, Werner J, Schiergens T. Specific management of patients with acute abdomen during the COVID-19 pandemic: a surgical perspective from Germany. *Visc Med.* 2020.
4. Saeed U, Sellevoll HB, Young VS, Sandbaek GT, Glomsaker T. Mala: COVID-19 may present with acute abdominal pain. *Br J Surg.* 2020;107(7):186-7.
5. Poggiali E, Ramos PM, Bastoni D, Vercelli A, Magnacavallo A. Abdominal pain: a real challenge in novel COVID-19 infection. *Euro J Case Rep Inter Med.* 2020;7(4).

Cite this article as: Shankar M, Chaudhary MK, Samal S, Ramchandani R. Emergency surgery amid ongoing pandemic in suspected COVID-19 with D1 perforation. *Int Surg J.* 2020;7(9):3169-71.