

## Case Report

# Operated case of tubercular meningitis with hydrocephalus in an immunocompromised patient and acute abdomen-management controversy: a case report

Amar Nath\*

Department of Neurosurgery, Pt. B. D. Sharma, PGIMS, Rohtak, Haryana, India

**Received:** 20 August 2021

**Revised:** 04 September 2021

**Accepted:** 06 September 2021

### \*Correspondence:

Dr. Amar Nath,

E-mail: amarnathmch@gmail.com

**Copyright:** © the author(s), publisher and licensee Medip Academy. This is an open-access article distributed under the terms of the Creative Commons Attribution Non-Commercial License, which permits unrestricted non-commercial use, distribution, and reproduction in any medium, provided the original work is properly cited.

### ABSTRACT

Tuberculosis is a very common infectious disease in developing countries like India. Most common form includes pulmonary tuberculosis. Other common forms are tubercular meningitis and intestinal tuberculosis. Hydrocephalus is one of the commonest complications of tubercular meningitis. We present a HIV positive case who had tubercular meningitis with hydrocephalus and was operated for ventriculoperitoneal shunting, later developed intestinal tuberculosis with perforation peritonitis. The presentation of an acute abdomen with a ventriculo-peritoneal shunt requires skillful diagnostic workup and management. Apart from complications caused by the shunt, primary abdominal pathological conditions must be taken into consideration. Tuberculosis has multiple presentations all of which should be kept in mind.

**Keywords:** Tubercular meningitis, Intestinal tuberculosis, Ventriculo-Peritoneal shunting

### INTRODUCTION

Tuberculosis is a very common infectious disease in developing countries like India.<sup>1,2</sup> Most common form includes pulmonary tuberculosis. Other forms are tubercular meningitis, intestinal tuberculosis, renal tuberculosis etc. These systemic manifestations are much more common in immunodeficient patients like patients suffering from HIV/DM.<sup>3</sup> We report such a case who presented with different complications arising from tuberculosis during the course of her treatment and led to management controversy.

### CASE REPORT

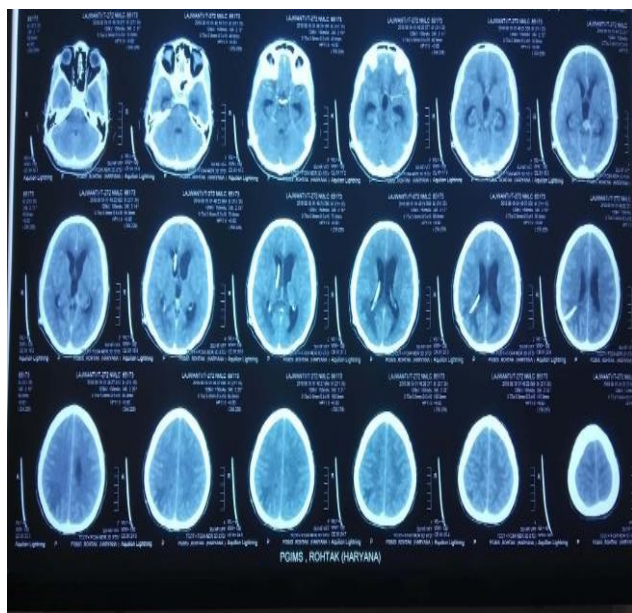
A 36 years female patient presented to emergency department with complaints of severe headache and recurrent vomiting for 7 days. The patient did not have any history of similar complaints in the past. She was

HIV positive for past 7 years for which no treatment was prescribed to her. She was on CD4 count monitoring. She had no history of any surgery or ATT in the past. On examination, GCS of patient was E4V5M6, pulse rate was 78/min, BP was 136/84 mmHg. Her neurological examination was within normal limits.

On blood investigations, her Hb was 7.8 gm/dL with a predominantly microcytic hypochromic picture. Her TLC was 7800 per mm<sup>3</sup>, DLC was 50/45/3/2, platelets count was 3.6 lacs/mm<sup>3</sup>. Her INR was 1.06 and all other blood investigations were within normal limits.

MRI brain was done which showed left thalamic granuloma with obstructive hydrocephalus (? Tubercular). A decision was made to operate the patient for hydrocephalus. A ventriculoperitoneal shunt was done and phenytoin and dexamethasone were started. The CSF was sent for cell counts, ADA levels and biochemical

examination which showed proteins level of 15 mg/dL, sugar levels of 71 mg/dL and ADA levels were 13.7 along with predominantly lymphocytic cytological picture and was suggestive of tuberculosis. Category 2 anti-tubercular treatment started. ART was also started on taking opinion from ART clinic and patient was discharged on 12<sup>th</sup> post-operative day under all satisfactory conditions.



**Figure: Plain CT scan head suggestive of hydrocephalus with shunt *in situ* and edema along shunt catheter.**

She again presented in emergency department six months later with complaints of pain abdomen, bilious vomiting and non-passage of stool and flatus for three days. On examination, her pulse rate was 98/min, BP was 94/62 mmHg. On per abdominal examination, distension was present with generalized tenderness and guarding. Her blood work showed leukocytosis with absolute lymphocytosis and hypoproteinemia. All other blood investigations were normal. Her abdominal x-ray showed multiple air fluid levels with dilated jejunal and ileal loops. Her USG abdomen showed free fluid in abdominal cavity and pelvis. Then, patient was operated and laparotomy done in emergency department. Her operative notes suggested as-Multiple strictures were present in terminal ileum with distended small bowel proximal to strictures. Two pinpoint perforations were present just proximal to the stricture. Resection of gut containing the strictures and perforation was done and end ileostomy was done. She was then shifted to surgery ward. Her hospital record suggests-Patient remained stable in post-operative period and ileostomy became functional on 3<sup>rd</sup> post-op day after which Ryle's tube was taken out and patient was allowed orally. Patient was discharged under all satisfactory conditions on 13<sup>th</sup> post-op day. Her histopathology report was suggestive of granulomatous

inflammation in bowel wall for which anti-tubercular treatment was continued.

After completion of antitubercular treatment for one year, patient was operated for ileostomy closure. The postoperative period was uneventful and after complete recovery, she was discharged on 7<sup>th</sup> post-operative day.

Patient again presented to us in emergency department with complaints of headache and vomiting after around six months of ileostomy closure. All her blood work-up was normal. Her NCCT head showed hydrocephalus with peri shunt catheter edema. A diagnosis of shunt block with meningitis due to ascending infection was made as induration was also present along shunt tube in neck and chest wall. She was managed conservatively with IV antibiotics and IV fluids. Phenytoin and decongestants were added to the treatment along with acetazolamide. Her CSF examination revealed no abnormality. Patient got relieved after 2 days of conservative management and she was discharged on 14<sup>th</sup> day of admission.

## DISCUSSION

Hydrocephalus is one of the commonest complications of tubercular meningitis (TBM), and its incidence is increasing with HIV global epidemic.<sup>3</sup> The management of hydrocephalus can include medical therapy with dehydrating agents and steroids for patients in good grades and those with communicating hydrocephalus.<sup>4,5</sup> However, surgery is required for patients with obstructive hydrocephalus and those in poor grades.<sup>5</sup> Literature evaluating role of ventriculo-peritoneal shunts in HIV-positive patients with TBM and hydrocephalus and also their long-term prognosis is scarce.<sup>7</sup>

The presentation of an acute abdomen with ventriculo-peritoneal shunt *in situ* may present diagnostic dilemma. Apart from complications caused by the shunt, primary abdominal pathological conditions must be taken into consideration. An acute abdomen due to shunt infection should be managed conservatively or by removal of the shunt from the abdomen, thus avoiding an unnecessary laparotomy. On the other hand, a primary intra-abdominal disease requires surgical treatment, during which the shunt system can be left in place or exteriorized depending upon clinical condition of patient and intraoperative findings whether localized or generalized contamination is present as exteriorization of shunt is not without hazards and balanced decision should be taken.<sup>8</sup>

## CONCLUSION

Tuberculosis is a common disease in India and is even commoner in HIV infected patients. Tuberculosis has multiple presentations all of which should be kept in mind. A complicated shunt in abdomen and acute abdomen due to some other intra-abdominal pathology is to be kept in mind and care should be taken while making a decision.

*Funding: No funding sources*

*Conflict of interest: None declared*

*Ethical approval: Not required*

## REFERENCES

1. Chadha VK. Tuberculosis epidemiology in India: a review. *Int J Tuberc Lung Dis.* 2005;9(10):1072-82.
2. Chakraborty AK. Epidemiology of tuberculosis: current status in India. *Indian J Med Res.* 2004;120(4):248-76.
3. Williams BG, Granich R, Chauhan LS, Dharmshaktu NS, Dye C. The impact of HIV/AIDS on the control of tuberculosis in India. *Proc Natl Acad Sci USA.* 2005;102(27):9619-24.
4. Rizvi I, Garg RK, Malhotra HS, Kumar N, Sharma E, Srivastava C et al. Ventriculo-peritoneal shunt surgery for tuberculous meningitis: A systematic review. *J Neurol Sci.* 2017;375:255-63.
5. Rajshekhar V. Management of hydrocephalus in patients with tuberculous meningitis. *Indian Perspective.* 2009;57(4):368-74.
6. Peng J, Deng X, He F, Omran A, Zhang C, Yin F, Liu J. Role of ventriculoperitoneal shunt surgery in grade IV tubercular meningitis with hydrocephalus. *Childs Nerv Syst.* 2012;28(2):209-15.
7. Sharma RN, Pruthi N, Arimappamagan A, Somanna S, Devi BI, Pandey P. Tubercular meningitis with hydrocephalus with HIV co-infection: role of cerebrospinal fluid diversion procedures. *J Neurosurg.* 2015;122(5):1087-95.
8. Pumberger W, Löbl M, Geissler W. Appendicitis in children with Ventriculoperitoneal Shunt. *Pediatr Neurosurg.* 1998;28:21-6

**Cite this article as:** Nath A. Operated case of tubercular meningitis with hydrocephalus in an immunocompromised patient and acute abdomen-management controversy: a case report. *Int Surg J* 2021;8:3165-7.