

Original Research Article

Validity of no-zone approach for management of isolated penetrating neck injuries in hemodynamically stable patients

Kamal A. M. Hassanein¹, Osama A. Ismail^{2*}, Islam A. Amer¹,
Ahmed Abdel Kahaar Aldardeer³, Tarek Elsayed Ftohy¹, Ahmed Gaber Hassanein¹

¹Maxillofacial Head and Neck Surgery Unit, Faculty of Medicine, Sohag University, Sohag, Egypt

²Department of Vascular Surgery, Faculty of Medicine, Sohag University, Sohag, Egypt

³General Surgery Department, Faculty of Medicine, Sohag University, Sohag, Egypt

Received: 25 August 2021

Accepted: 09 September 2021

*Correspondence:

Dr. Osama A. Ismail,

E-mail: oelnahaas@yahoo.com

Copyright: © the author(s), publisher and licensee Medip Academy. This is an open-access article distributed under the terms of the Creative Commons Attribution Non-Commercial License, which permits unrestricted non-commercial use, distribution, and reproduction in any medium, provided the original work is properly cited.

ABSTRACT

Background: Routine neck exploration for isolated penetrating neck injuries (PNIs) in hemodynamically stable patients increases the frequency of unnecessary interventions and complications. Current management protocol involves the no zone approach which uses physical examination and computerized tomographic angiography (CTA) to guide treatment. The aim was to assess the validity of the no-zone approach in the management of isolated PNIs in hemodynamically stable patients.

Methods: This retrospective study included patients with isolated PNIs with soft signs who were hemodynamically stable. They were classified into patients with negative CTA findings and were managed conservatively and patients with positive CTA findings suspecting aerodigestive tract injuries (ADTIs) who were submitted to further selective investigations to confirm or rule out these injuries. Detected injuries were managed accordingly.

Results: This study included 106 PNIs patients who had soft signs and were hemodynamic stable. 37 cases (34.9%) had negative CTA findings and were managed conservatively. Sixty nine patients (65.1%) had positive CTA findings and were subjected to subsequent selective investigations and revealed 3 patients with negative endoscopic findings who passed without need for any surgical intervention. Therefore, 40 (37.7%) patients were saved from surgery with no missed injuries. Patients with definitive injuries (66 patients) underwent neck exploration and managed accordingly. No missed injuries were recorded in this study. Complications were detected in 6 cases (5.7%) while death was recorded in 2 cases (1.9%).

Conclusions: No-zone approach offers a safe management protocol for isolated PNIs in hemodynamically stable patients. It provides no missed injuries, negligible rates of negative exploration and minimal complications and mortality.

Keywords: No-zone approach, Management, Penetrating neck injuries

INTRODUCTION

PNIs can induce complex damage to vital structures, vascular, respiratory, digestive and neurological structures.¹ They accounts for 5-10% of all trauma cases with high incidence with violence, traffic accidents, homicidal and suicidal attempts.² Mortality rate reaches up to 11% with major vascular injuries.³

Neck exploration has been the standard protocol in management of PNIs to avoid missed injuries.⁴ This policy has been learned from military surgical practice in the last century.⁵ Surgeons used to utilize the zone-based approach to guide investigations and management with very low rates of missed injuries and high rates of successful conservative management. Zones of neck injury were recorded according to Roon and

Christensen's modification.⁶ Zone I from the base of the neck to the cricoid cartilage, zone II from cricoid cartilage to the angle of the lower jaw and zone III area above the angle of the lower jaw. Although zones of the neck can offer important guidelines in management of PNIs, zone-based approach has some disadvantages especially the poor correlation between the site of neck wounds and internal structures involvement.⁷ Additionally, sometimes neck injuries may be located at more than one level which make more confusion and dilemma in decision making.⁸ Also, zone based approach may result in high rate of unnecessary explorations with its possible complications and misuse of resources. Therefore, recently, the no-zone approach has emerged as a new strategy depending mainly upon physical examination and computed tomography angiography (CTA) in guiding the treatment plan especially for vascular and aerodigestive injuries with insignificant missed lesions and negative exploration rates ~1-2%.⁴

In the presence of hemodynamic instability or hard signs suggestive of injured vital structures, surgical exploration is mandatory even without need to imaging investigations as these injuries are life threatening conditions.⁷ Hemodynamic stability doesn't exclude injury to underlying structures but also, it didn't indicate urgent intervention and therefore, it should be thoroughly investigated and closely monitored.⁹ Hard signs include hoarseness, gas bubbling, profuse bleeding, expanding hematomas or hemodynamic instability, while soft signs include dysphagia, crepitation, stable hematoma, hemoptysis or hematemesis.^{10,11}

The aim of this study was to evaluate the no-zone approach for the management of isolated PNIs in hemodynamically stable patients in our locality.

METHODS

This retrospective study had been conducted at Sohag university hospitals, Sohag, Egypt and carried out on patients with isolated PNIs with soft signs and were hemodynamically stable in the period from July 2016 to December 2020. This study was approved by the Institutional Review Board (IRB) and Ethics Committee. As the study was retrospective, the informed consent was waived. Polytraumatized patients associated with other body injuries, cervical spine or spinal cord injuries and PNIs associated with hard signs were excluded from the study.

Demographic data, hemodynamic status, hematocrit values, details and manifestations of neck injury were collected and reviewed. Duplex US and CTA were performed in all cases while endoscopic assessment, oesophagoscopy and/or bronchoscopy were performed selectively. Operative details, negative exploration, missed injury rates, mortality rates and postoperative complications were collected and analyzed.

According to the clinical findings and CTA results, patients were classified into patients with negative CTA findings and they were closely observed by frequent physical examination; patients with positive CTA findings suspecting aerodigestive tract injuries (ADTs) and they were submitted to further selective investigations e.g. esophagoscopy or bronchoscopy to confirm or rule out these injuries.

Cases with positive CTA findings confirmed by selective investigations were subjected to surgical management. Surgery was initiated by ensuring a patent airway followed by management of the detected injured structure. Surgical repair was performed for laryngotracheal injuries including skeletal injuries or accompanying soft tissue injuries. Non-displaced fractures of the laryngeal skeleton were managed conservatively.

Management of vascular injuries was started by attempts of bleeding control by proximal and distal clamping of injured vessels. In attempting repair of associated arterial injuries, unfractionated heparin (5000 IU) was administered intraoperatively and continued postoperatively by low molecular weight heparin 40 IU once daily. Both proximal and distal ends of the injured vessels were cleared from blood clots and flushed with heparinized saline. Saphenous vein graft was used when there was an indication for patch or interposition graft. Repaired vessels were covered with muscles and soft tissues to protect the vascular repair from potential infection and guard against vessel blow-out. Vessel ligation was an option in certain conditions of vascular injuries e.g. multiple injuries of external carotid artery (ECA), internal jugular vein (IJV), external jugular vein (EJV) and other minor vessels.

Pharyngeal injuries were repaired with polydioxanone sutures and a transposed sternomastoid muscle flap was mobilized over the repair. Simple esophageal injuries were managed by direct suture repair and drainage, while extensive injuries underwent debridement and drainage with a planned delayed repair.

Recorded complications in this study were classified into vascular, respiratory, pharyng-oesophageal complications and infections. All patients were followed up postoperatively during the hospital stay, once weekly in the first month and then monthly until 6 months.

Study outcomes

Rates of missed injury, negative exploration, complications and mortality were the study outcomes.

Statistical analysis

Statistical analysis was done by SPSS program. Quantitative data was expressed as means±SD while

qualitative data were expressed as numbers and percentage.

RESULTS

Revising patients files on the accident and emergency unit had revealed that there were 350 patients presented with PNIs during the period between July 2016 and December 2020. Two hundreds and four patients were polytraumatized and were excluded from the study. Forty

patients were presented PNIs with hemodynamic instability and were subjected to immediate neck exploration and were also excluded. The remaining 106 patients had PNIs with soft signs and were hemodynamic stable. Those patients were enrolled in this study (Figure 1). They were 90 males (84.9%) and 16 females (15.1%). Their ages ranged between 12 and 69 years with a mean of 38±13.2 years. The etiology of injury was road traffic accident in 63 cases (59.4%), assault in 27 cases (25.5%), occupational in 13 cases (12.3%) and deliberate self-harm in 3 cases (2.8%) (Table 1).

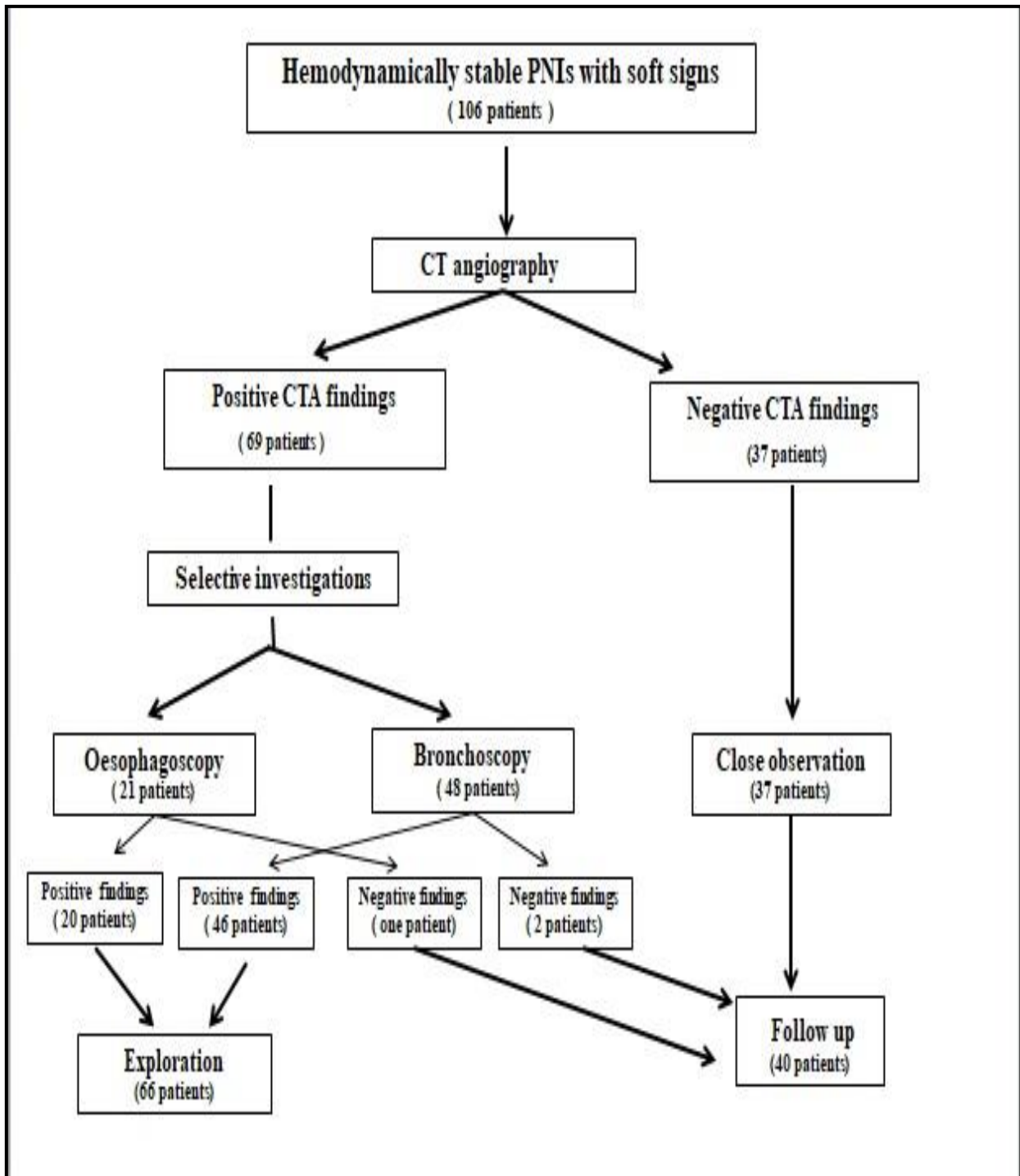


Figure 1: Algorithm for management of PNIs.

Table 1: Demographic data and patients criteria (n=106).

Variables	N (%)
Age groups (in years)	
10-20	3 (2.8)
21-30	15 (14.2)
31-40	34 (32.1)
41-50	28 (26.4)
51-60	18 (17)
61-70	8 (7.5)
Gender	
Male	90 (84.9)
Female	16 (15.1)
Etiology of injury	
Road traffic accident	63 (59.4)
Criminal assault	27 (25.5)
Occupational	13 (12.3)
Deliberate self-harm	3 (2.8)

Table 2: Classification of neck injuries according to neck zones (n=106).

Neck zones	N (%)
Zone I	21 (19.8)
Zone II	64 (60.4)
Zone III	14 (13.2)
Combined	7 (6.6)

Zone II was the most commonly injured area (60.4%) followed by zone I (19.8%) and zone III (13.2%). Seven patients (6.6%) had multiple or extensive neck injuries and could not be described as a single zone (Table 2).

Thirty-seven cases (34.9%) had negative CTA findings and were managed conservatively by close monitoring. There were no recorded missed injuries requiring subsequent neck exploration among all patients undergoing conservative treatment.

Sixty nine patients (65.1%) had positive CTA findings. Those patients were subjected to subsequent selective investigations based on the findings in CTA; oesophagoscopy in 21 patients and bronchoscopy in 48 patients. Oesophagoscopy was confirmative for esophageal injuries in 20 patients and was negative in one patient while bronchoscopy proved laryngo-tracheal injuries in 46 patients and was negative in 2 patients. Patients with negative endoscopic findings (3 patients) were managed thoroughly by close follow up to identify any missed injuries. Those patients passed smoothly without need for any surgical intervention.

Therefore, 40 (37.7%) patients, 37 patients with negative CTA findings as well as 3 patients with negative endoscopic findings were saved from surgical exploration with its morbidity and possible complications.

Patients with definitive injuries (66 patients) underwent neck exploration and revealed laryngotracheal injuries in 33 cases (31.1%), pharyngeal injuries in 8 cases (7.5%) and esophageal injuries in 11 cases (10.4%). Combined injuries with associated vascular injuries in 13 cases (12.3%). Negative exploration was recorded in one patient (0.9%) (Table 3).

Table 3: Management strategy (n=106).

Modality of treatment	N (%)
Conservation	40 (37.7)
Surgical management	66 (62.3)
Laryngotracheal injuries	33(31.1)
Pharyngeal injuries	8 (7.5)
Esophageal injuries	11 (10.4)
Combined injuries	13 (12.3)

Table 4: Details of vascular injuries.

Details of vascular injuries	N (%)
Type of injured vessel	
Arterial injuries	2 (1.9)
Venous injuries	7 (6.6)
Combined	4 (3.8)
Type of injury	
Incomplete transection	6 (5.7)
Complete transection	4 (3.8)
Thrombosed vessel	3 (2.8)
Methods of vascular management	
Primary repair	4 (3.8)
Venous patch repair	1 (0.9)
Interposition vein graft	1 (0.9)
Vessel ligation	7 (6.6)

Table 5: Complications.

Complications	N (%)
Vascular complications	1 (0.9)
Respiratory complications	1 (0.9)
Pharyngoesophageal complications	2 (1.9)
Infections	3 (2.8)

Table 6: Study outcomes.

Study outcomes	Value
	N (%)
Missed injury rate	0 (0)
Negative exploration rate	1 (0.9)
Mortality rate	2 (1.9)

Associated vascular injuries were arterial injuries in 2 patients (1.9%), venous injuries in 7 patients (6.6%) and combined arterial and venous injuries in 4 patients (3.8%). ECA or one of its branches (4 cases) in addition to IJV (2 cases) were the commonly injured vessels. However, multiple perforations to the common carotid

artery (CCA) were detected in 2 cases and the other venous injuries were detected in EJV and small venous branches. Primary repair was performed in 4 cases, 3.8% (2 cases of ECA and 2 cases of IJV). CCA injuries were managed by vein patch in one case (0.9%), and interposition vein graft in the other case (0.9%). Ligation of injured vessels was performed in 7 patients (6.6%) (Table 4).

Complications were detected in 6 cases (5.7%). Vascular complications were detected in one case in the form of carotid blow out caused by secondary infection. This patient couldn't be saved and died. Respiratory complications were reported in another case in the form of tracheal stenosis and this patient was referred to cardiothoracic surgery. Pharyngo-oesophageal complications occurred in 2 patients in the form of pharyngo-cutaneous fistula, one healed spontaneously after conservative treatment within three weeks while the other was managed surgically. Infections were reported in 3 cases, one was severe deep neck infection complicated by carotid blow out and death, the other was superficial wound infection and was treated medically and the 3rd one was descending mediastinitis that not responding to surgical treatment and died because of multiple organ failure. Mortality rate was recorded in 2 cases (1.9%), mediastinitis in one case and carotid blow out in the other (Table 5).

DISCUSSION

PNIs were common presentation in emergency and causality unit. The management was debatable between mandatory exploration and conservative approach. This challenge came from the algorithm of zone-based management suggesting mandatory exploration in both hemodynamically stable or unstable patients especially with zone II injuries while vascular investigations were required in stable zone I and III injuries. This concern achieved 65% success rate.¹² Investigators found that patients with soft signs couldn't need operative management with negative predictive value of 100%.⁴ Therefore, the conservative measures in stable patients regardless the zone seemed to be a considerable approach. On the contrary, the eastern guidelines confirmed that selective non-operative treatment is equally justified and safe compared with mandatory exploration in patients with soft signs and hemodynamically stable even in zone II injuries.¹³

It was evident that urgent neck exploration was mandatory in hemodynamically unstable patients with positive hard signs regardless its negative exploration rate that may reach up to 10-27%.¹⁴ Zone-based approach had many disadvantages, high negative exploration rates, poor correlation between the location of external neck wound and internal injured structures and also, patients with multiple or transcervical injuries occasionally can't be classified into a definite zone.⁷

The collected data of this series was matched with other studies where there was a high incidence of air way injury in 33 cases (31.1%) followed by pharyngo-oesophageal (17.9%) respectively.⁷ Injuries of the esophagus were less common because of its deep location in the neck and its protection by the surrounding structures.

CTA was performed as the main diagnostic tool in all cases with soft signs of neck injuries. The common CTA findings suggestive of ADTIs were deep surgical emphysema, paratracheal air, tracheal wall discontinuity, tracheal rings fracture or deformity.¹⁵ Joanna et al discussed the role of CT angiography in detection of ADTIs and concluded that CTA was very helpful in esophageal and tracheal injuries with sensitivity up to 97.4% and appreciated the CTA as mainstay imaging modality following trauma evaluation.¹⁶ CTA provided other advantages with high sensitivity and specificity in detection of vascular, other soft tissue injuries. Additionally, it can offer data on the injury trajectory.¹⁷ However, CTA can't be relied upon in suspicion of esophageal injuries and therefore, flexible esophagoscopy should be performed. Flexible esophagoscopy had high sensitivity rate close to 100%.¹⁸ Andre et al had concluded in his series that absence of deep surgical emphysema in the deep neck fascial planes excludes surgically significant ADTIs but its presence was nonspecific and warrants further investigation.¹⁹ This concept was respected in this series where oesophagoscopy was performed in 21 patients and bronchoscopy in 48 patients due to suspected CTA findings. Oesophagoscopy was confirmative in 20 patients (95.2%) and was negative in one patient (4.8%) while bronchoscopy proved laryngo-tracheal injuries in 46 patients (95.8%) and was negative in 2 patients (4.2%).

In this series no zone approach was prescribed for management of PNIs with soft signs and therefore, surgical intervention was tailored according to the expected injuries. In this series, surgical intervention was done in 66/106 cases (62.3%) while 40/106 cases (37.7%) had saved from surgical intervention and its consequences regarding morbidity and mortality. Siau et al and others had reported that no zone approach was seen to be safe with few negative explorations and minimal missed injury.^{4,20} No missed injuries were recorded in this study. Similarly, Thoma et al followed the same algorithm in management of their patients based on clinical examination and CTA and reported no missed injuries.²¹

Vascular injuries should be managed immediately after ensuring patent airway and before starting management of any other associated injuries. Vascular injuries were detected in 13 cases (12.3%). Venous injuries were detected in seven cases (6.6%). The commonest form was incomplete transection (5.7%). The commonly used techniques were simple repair, vein patch or interposition

grafts. Ligation of injured vessel was performed in 7 patients (6.6%) due to multiple vascular injuries associated with neck injuries to save time. Toit et al reported that vessel ligation is an acceptable procedure in severe bleeding or presence of hypovolemic shock.²² Saito et al reported nearly similar incidences of vascular injuries.²³

Repair of vascular injuries requires proximal and distal control for the injured blood vessel. However, in certain circumstances such as very high cranial or very low caudal vascular injury, vessel control was challenging and sometimes difficult that may require access mandibulotomy or sternotomy. Fortunately, we didn't confront such cases. Hundesmarck et al reported that performance of hybrid technique; open surgery combined with endovascular interventions, using covered stent and found it more beneficial.¹

Pharyngeal repairs were performed in 8 patients (7.5%), while esophageal repairs were done in 11 patients (10.4%). These injuries were clinically suspected and precisely detected by CTA findings of deep surgical emphysema and confirmed by oesophagoscopy. When pharyngeal or esophageal injuries were detected, surgical repair must be performed early as these injuries may be complicated by mediastinitis, neck abscess or empyema due to leakage of their contents.²¹

Complications were noticed in 6 cases (5.7%). Infections were the commonest complications (3 cases, 2.8%). Vascular complications included secondary post-operative hemorrhage caused by carotid blow-out and was reported in one case. Respiratory complication was encountered in one case in the form of tracheal stenosis. Pharyngo-cutaneous fistula was reported in 2 cases; one healed spontaneously after conservative treatment within three weeks while the other was managed surgically. Mortality rate in this series was 2 patients (1.9%).

Agreeing with this management protocol; no-zone approach, it was found that 40 patients (37.7%) had been escaped from unnecessary neck exploration with its known morbidity and mortality. Those patients passed smoothly in postoperative period during follow up with no missed injuries. Therefore, PNIs in stable hemodynamic patients shouldn't be routinely explored but also, they should be thoroughly investigated by CTA and selective investigations and closely monitored.

CONCLUSION

No-zone approach offers a safe management protocol for isolated PNIs in hemodynamically stable patients. It provides no missed injuries, negligible rates of negative exploration and minimal complications and mortality.

Funding: No funding sources

Conflict of interest: None declared

Ethical approval: The study was approved by the Institutional Ethics Committee

REFERENCES

- Hundesmarck D, Folmer ER, deBorst GJ, Leenen LP, Vriens PW, Hietbrink F. Penetrating neck injury in two Dutch level 1 trauma centres: the non-existent problem. *Eur J Vascul Endovasc Surg.* 2019;58(3):455-62.
- Mahmoodie M, Sanei B, Moazeni-Bistgani M, Namgar M. Penetrating neck trauma: review of 192 cases. *Arch Trauma Res.* 2012;1(1):14.
- Ozturk K, Keles B, Cenik Z, Yaman H. Penetrating zone II neck injury by broken windshield. *Int Wound J.* 2006;3(1):63-6.
- Prichayudh S, Choadrachata-Anun J, Sriussadaporn S, Pak-Art R, Sriussadaporn S, Kritayakirana K, et al. Selective management of penetrating neck injuries using "no zone" approach. *Injury.* 2015;46(9):1720-5.
- Fitchett VH, Pomerantz M, Butsch DW, Simon R, Eiseman B. Penetrating wounds of the neck: a military and civilian experience. *Arch Surg.* 1969;99(3):307-14.
- Roon AJ, Christensen N. Evaluation and treatment of penetrating cervical injuries. *J Trauma.* 1979;19(6):391-7.
- Low GM, Inaba K, Chouliaras K, Branco B, Lam L, Benjamin E, et al. The use of the anatomic 'zones' of the neck in the assessment of penetrating neck injury. *Am Surge.* 2014;80(10):970-4.
- Shiroff AM, Gale SC, Martin ND, Marchalik D, Petrov D, Ahmed HM, et al. Penetrating neck trauma: a review of management strategies and discussion of the 'no zone' approach. *Am Surge.* 2013;79(1):23-9.
- Burgess C, Dale O, Almeyda R, Corbridge R. An evidence based review of the assessment and management of penetrating neck trauma. *Clinic Otolaryngol.* 2012;37(1):44-52.
- Sperry JL, Moore EE, Coimbra R, Croce M, Davis JW, Karmy-Jones R, et al. Western Trauma Association critical decisions in trauma: penetrating neck trauma. *J Trauma Acute Care Surg.* 2013;75(6):936-40.
- Demetriades D, Theodorou D, Cornwell E, Berne T, Asensio J, Belzberg H, et al. Evaluation of penetrating injuries of the neck: prospective study of 223 patients. *World J Surg.* 1997;21(1):41-8.
- Sekharan J, Dennis JW, Veldenz HC, Miranda F, Frykberg ER. Continued experience with physical examination alone for evaluation and management of penetrating zone 2 neck injuries: results of 145 cases. *J Vasc Surg.* 2000;32(3):483-9.
- Tisherman SA, Bokhari F, Collier B, Ebert J, Holevar M, Cumming J, et al. Clinical practice guidelines: penetrating neck trauma. EAST. 2008.
- Inaba K, Branco BC, Menaker J, Scalea TM, Crane S, DuBose JJ, et al. Evaluation of multidetector computed tomography for penetrating neck injury: a prospective multicenter study. *J Trauma Acute Care Surg.* 2012;72(3):576-84.

15. Chen JD, Shanmuganathan K, Mirvis SE, Killeen KL, Dutton RP. Using CT to diagnose tracheal rupture. *Am J Roentgenol.* 2001;176(5):1273-80.
16. Madsen AS, Oosthuizen G, Laing GL, Bruce JL, Clarke DL. The role of computed tomography angiography in the detection of aerodigestive tract injury following penetrating neck injury. *J Surg Res.* 2016;205(2):490-8.
17. Inaba K, Munera F, McKenney M, Rivas L, DeMoya M, Bahouth H, et al. Prospective evaluation of screening multislice helical computed tomographic angiography in the initial evaluation of penetrating neck injuries. *J Trauma Acute Care Surg.* 2006;61(1):144-9.
18. Lourencao J, Nahas S, Margarido N, Aj RJ, Birolini D. Penetrating trauma of the neck: prospective study of 53 cases. *Revista do Hospital das Clínicas.* 1998;53(5):234-41.
19. Madsen AS, Oosthuizen GV, Bruce JL, Bekker W, Laing GL, Clarke DL. Selective nonoperative management of pharyngoesophageal injuries secondary to penetrating neck trauma: a single-center review of 86 cases. *J Trauma Acute Care Surg.* 2018;85(3):541-8.
20. Siau RT, Moore A, Ahmed T, Lee MS, Tostevin P. Management of penetrating neck injuries at a London trauma centre. *Eur Arch Oto Rhino Laryngol.* 2013;270(7):2123-8.
21. Thoma M, Navsaria PH, Edu S, Nicol AJ. Analysis of 203 patients with penetrating neck injuries. *World J Surg.* 2008;32(12):2716-23.
22. DuToit D, Coolen D, Lambrechts A, Odendaal JV, Warren B. The endovascular management of penetrating carotid artery injuries: long-term follow-up. *Eur J Vasc Endovasc Surg.* 2009;38(3):267-72.
23. Saito N, Hito R, Burke PA, Sakai O. Imaging of penetrating injuries of the head and neck: current practice at a level I trauma center in the United States. *Keio J Med.* 2014;63(2):23-33.

Cite this article as: Hassanein KAM, Ismail OA, Amer IA, Aldardeer AAK, Ftohy TE, Hassanein AG. Validity of no-zone approach for management of isolated penetrating neck injuries in hemodynamically stable patients. *Int Surg J* 2021;8:2885-91.