

Case Report

A case of acute gangrenous cholecystitis in an ectopic left sided gallbladder: a challenging laparoscopic cholecystectomy

Seema Barman, Manmohan Kamat, Varsha Sharma*, Jeena Sathyan, Shravani Shetye

Department of General Surgery, Dr. Balabhai Nanavati Hospital, Mumbai, Maharashtra, India

Received: 29 June 2022

Accepted: 29 July 2022

***Correspondence:**

Dr. Varsha Sharma,

E-mail: varsha.sharma70@yahoo.com

Copyright: © the author(s), publisher and licensee Medip Academy. This is an open-access article distributed under the terms of the Creative Commons Attribution Non-Commercial License, which permits unrestricted non-commercial use, distribution, and reproduction in any medium, provided the original work is properly cited.

ABSTRACT

Left sided gallbladder is a rare entity and can be associated with other anomalies of portal vein and biliary system. It can be dangerous as it can create clinical confusion and hence radiological identification with the help of CT scan or USG is of great importance. A 60 years old lady, presented with pain and tenderness in the epigastrium and right hypochondrium, on USG got diagnosed with acute cholecystitis. Intra operatively she was found to have a gangrenous left sided ectopic gallbladder (GB). The incidence of ectopic GB is only 0.1-0.7% and can be found in wide range of locations including the lesser omentum, the retro-duodenal area, falciform ligament, abdominal wall muscles. Mal-positioning of the gallbladder can confound presenting signs and symptoms of the disease creating technical problems during surgical procedures and hence it is advised to always resect it out whenever diagnosed.

Keywords: Ectopic gall bladder, Gangrenous cholecystitis, Difficult laparoscopic gallbladder

INTRODUCTION

Left-sided gallbladder is defined as a gallbladder located to the left side of the ligamentum teres. This anomaly can be divided into three anatomic abnormalities: a situs inversus, an ectopic left-sided gallbladder, and a right-sided ligamentum teres.¹⁻⁴ Left-sided gallbladder with right-sided ligamentum teres has been a rare anomaly since Hochstetter's first description in 1886. Its characteristic description is a "gallbladder lying over the left side of the ligamentum teres".⁵ The associated anomalies with left-sided gallbladder include portal vein anomalies, biliary system anomalies and segment IV atrophy.⁵ An ectopic gall bladder is a dangerous entity as it can create clinical confusion. If it is situated away from the peritoneum, the typical signs of acute cholecystitis can be absent and peritoneal signs may not be seen.⁶ The anomalous position of the gall bladder can result in misinterpretation of imaging findings. Awareness of the possibility of such an anomaly facilitates proper diagnosis.⁶

Imaging helps the surgeon to plan a proper approach for an ectopic gall bladder. It has been recommended that cholecystectomy should be carried out for ectopic gall bladder, even in asymptomatic cases.^{6,7}

CASE REPORT

A 68 years old lady, came to emergency department with the chief complaints of pain in the epigastric region for 2 days, not radiating to other sites, associated with multiple episodes of vomiting, no history of fever, no history of lack of appetite or weight loss. No significant past medical or surgical history. No other comorbidities. On examination, she was afebrile to touch, pulse rate was 100 /min, blood pressure was 110/70 mmHg, respiratory rate was 18 breathes per minute. Per abdominal examination revealed tenderness in the epigastric and right hypochondriac region, with rest of the abdomen being soft. Her ultrasonogram was suggestive of acute cholecystitis and biliary sludge (Figure 1).

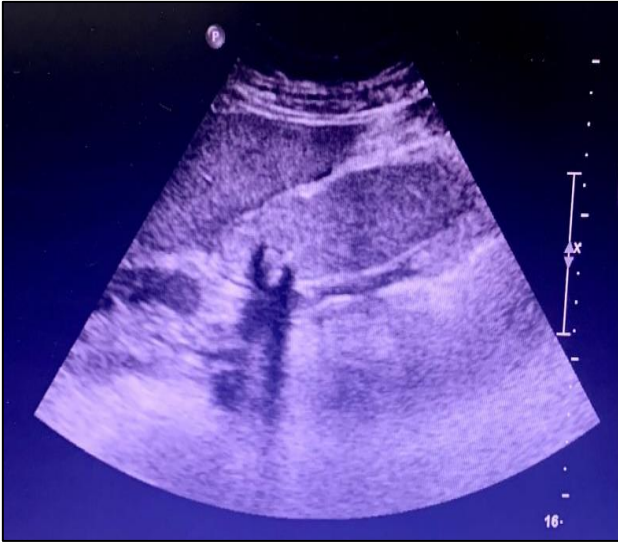


Figure 1: USG showing acute cholecystitis with biliary sludge.

She was taken up for laparoscopic cholecystectomy after routine pre-operative investigations.

Her intra-op findings were as follows: ectopic gall bladder transversely positioned to the left of the falciform ligament, gangrenous gall bladder and bulky falciform ligament (Figure 2).

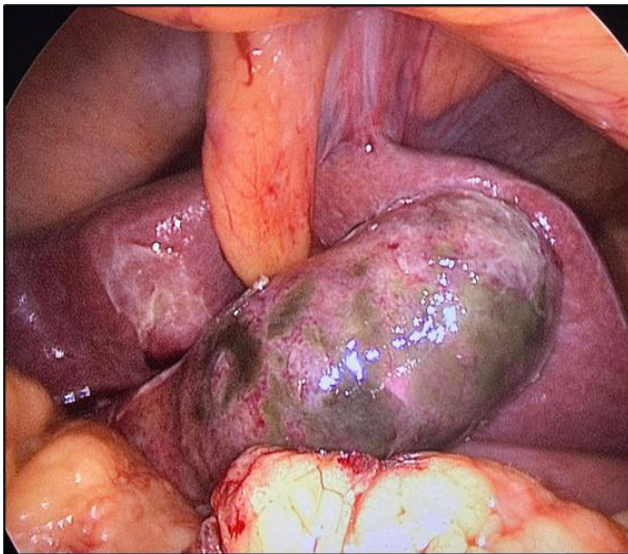


Figure 2: Transversely positioned ectopic GB (lying left to the falciform ligament) showing gangrenous changes.

Port placement was done as for a standard laparoscopic cholecystectomy procedure.

Cholecystectomy completed laparoscopically, procedure went uneventful, she recovered well and went home on post op day 3.

DISCUSSION

Ectopic location of the gall bladder is very rare, its incidence being 0.1-0.7 and are found in a wide range of locations; the more common is beneath the left lobe of the liver and left of the round ligament (as in this case), transversely positioned, intrahepatic or retro-placed, i.e., directly behind the liver or in the retroperitoneal space. Left-sided gallbladders and floating gallbladders that hang from a long mesentery within the abdomen or pelvis have also been reported.¹⁻³ Ectopic gall bladder has also been reported in the lesser omentum, the retro-duodenal area, falciform ligament, within the abdominal wall muscles, and within the thorax.⁴⁻⁶

The gallbladder is typically located under the right lobe of the liver, in the plane of the interlobar fissure.⁷ Embryologically, this organ arises from the caudal bud which itself originates from the hepatic diverticulum of the primitive midgut during the organogenesis of the liver, biliary tract, and ventral pancreas around the 4th week of gestation.⁸ The 4 most common ectopic locations of the gallbladder include under the left liver lobe, intrahepatic, transverse, and retro-placed. The incidence of an ectopic location of the gallbladder is reported to be 0.1-0.7%.⁹ Mal-positioning of the gallbladder is of great clinical significance as it can confound presenting signs and symptoms of infection and/or inflammation and create technical problems during cholecystectomy and other biliary operations.

A floating gallbladder may also be predisposed to torsion, particularly if provoked by nearby peristaltic bowel. Gallbladders beneath the left hepatic lobe are susceptible to herniation into the foramen of Winslow. For the above reasons it has been suggested that ectopic gallbladders should be resected when found.⁹

Suggestions were like-Epigastric port should be more on the left and down, leg split position will be helpful and computed tomography prior to planned surgery will be useful.

CONCLUSION

Left sided ectopic GB is rare, but can be dangerous as it can create clinical confusion and interfere with the standard management of GB diseases. Mal-positioning of GB (depending on the location) can create various complications during cholecystectomy or biliary surgeries and hence it is always advised to do a cholecystectomy even if the patient is asymptomatic. For left sided ectopic GB, standard port placement can be done for laparoscopic resection, placing the epigastric port more towards left side is beneficial.

Funding: No funding sources

Conflict of interest: None declared

Ethical approval: Not required

REFERENCES

1. Chowbey PK, Wadhwa A, Sharma A. Ectopic gall bladder: laparoscopic cholecystectomy. Surg Laparosc Endosc Percutan Tech. 2004;14:26-8.
2. Wong LS, Rusby J, Ismail T. Left-sided gall bladder: a diagnostic and surgical challenge. ANZ J Surg. 2001;71:557-8.
3. Meilstrup JW, Hopper KD, Thieme GA. Imaging of gall bladder variants. AJR Am J Roentgenol. 1991;157:1205-8.
4. Haaga JR, Herbener TE. The gall bladder and biliary tract. CT and MR of Imaging of the whole body; 4th ed. Missouri: Mosby, Inc. 2003;1341-94.
5. Meilstrup JW, Hopper KD, Hieme GA. Imaging of gall bladder variants. Am J Roentgenol. 1991;152:1205.
6. Blanton DE, Bream CA, Mandel SR. Gall bladder ectopia: A review of anomalies of position. Am J Roentgenol. 1974;121:396.
7. Rafailidis V, Varelas S, Kotsidis K, Rafailidis D. Two congenital anomalies in one: an ectopic gallbladder with phrygian cap deformity. Case Rep Radiol. 2014;2014:246476.
8. Ando H. Embryology of the biliary tract. Dig Surg. 2010;27:87-9.
9. Popli MB, Popli V, Solanki Y. Ectopic gall bladder: a rare case. Saudi J Gastroenterol. 2010;16:50.

Cite this article as: Barman S, Kamat M, Sharma V, Sathyan J, Shetye S. A case of acute gangrenous cholecystitis in an ectopic left sided gallbladder: a challenging laparoscopic cholecystectomy. Int Surg J 2022;9:1647-9.