

Case Series

Intestinal arteriovenous malformations: a diagnostic and therapeutic challenge

Lakshminarayan S. Bhat^{1*}, Kishore G. S. Bharathy², Sadiq S. Sikora²

¹Department of Surgical Gastroenterology, Max Super Specialty Hospital and Subbaiah Medical College, Shimoga, Karnataka, India

²Department of Surgical Gastroenterology, Institute of Digestive and HPB Sciences, Sakra World Hospital, Bengaluru, Karnataka, India

Received: 29 June 2022

Revised: 30 July 2022

Accepted: 01 August 2022

***Correspondence:**

Dr. Lakshminarayan S. Bhat,

E-mail: lachibhat@gmail.com

Copyright: © the author(s), publisher and licensee Medip Academy. This is an open-access article distributed under the terms of the Creative Commons Attribution Non-Commercial License, which permits unrestricted non-commercial use, distribution, and reproduction in any medium, provided the original work is properly cited.

ABSTRACT

Arteriovenous malformations (AVM) of the intestine are rare causes of gastrointestinal bleeding. Diagnosis depends upon accurate interpretation of imaging features and histopathology to differentiate them from other vascular malformations. Presentation of colonic AVM with mucous diarrhea and pain is rare and poses diagnostic challenges. Usually, patients presenting with bleed need surgical intervention. The current report discussed one patient with chronic liver disease, extrahepatic portal vein thrombosis with small bowel AVM and two patients with colonic AVM, highlighting management strategies adopted.

Keywords: Arteriovenous malformation, Gastrointestinal hemorrhage, Diarrhea, Management

INTRODUCTION

Gastrointestinal AVM are classically described in the colon, however can occur throughout the gastrointestinal tract. It contains dilated, thin-walled vessels that directly communicates from artery to vein. AVM may be found during evaluation of gastrointestinal (GI) bleeding or it may be discovered incidentally during an endoscopic evaluation. Usually, the bleeding tends to be recurrent and chronic.¹ When they present with symptoms other than bleeding, it might cause diagnostic and therapeutic challenge. This case series described diagnosis and management of such cases.

CASE SERIES

Case 1

A 55 years old gentleman presented with one day history of obscure gastro intestinal bleeding. Diagnosis of AVM

was made with CT angiography (Figure 1). Treated with emergency laparotomy and resection anastomosis of small bowel.

Case 2

A 35 years old, gentleman with no comorbidities, presented with loose stool, mucous discharge and dull aching lower abdominal pain of 20 days duration. Diagnosis was established with the help of CT angiography aided by colonoscopy and biopsy (Figure 2). Treated with resection anastomosis of the left colon and Hartmann's procedure followed by restoration of bowel continuity after 8 weeks.

Case 3

A 76 years old male patient with diabetes mellitus and hypertension presented with loose stool, increased mucous discharge and associated weight loss for 3

months. Diagnosis was established with CT angiography and MRI pelvis aided by colonoscopy and biopsy. Managed conservatively with medicines. Summary of all cases in Table 1.

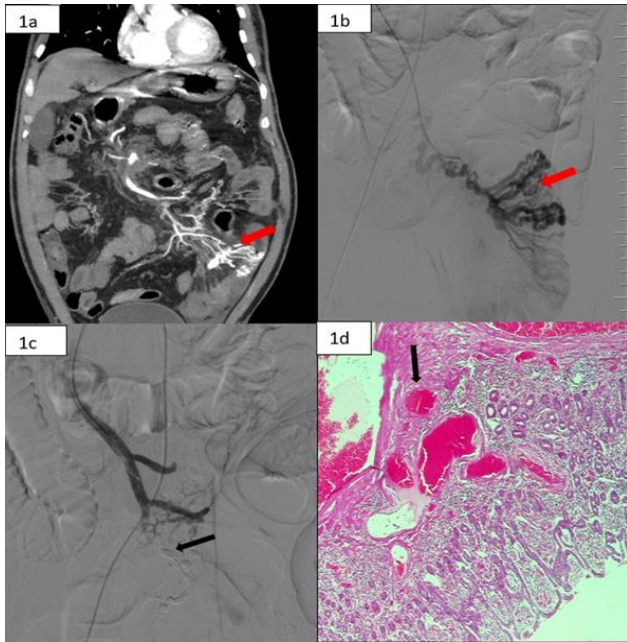


Figure 1 (A-D): CT scan arterial phase coronal view showing AVMs, vascular tufts (arrow); angiographic picture showing AVM (arrow); angiography post embolization partial occlusion of flow into AVM (arrow) and HPE low power showing multiple submucosal vascular channels (arrow).

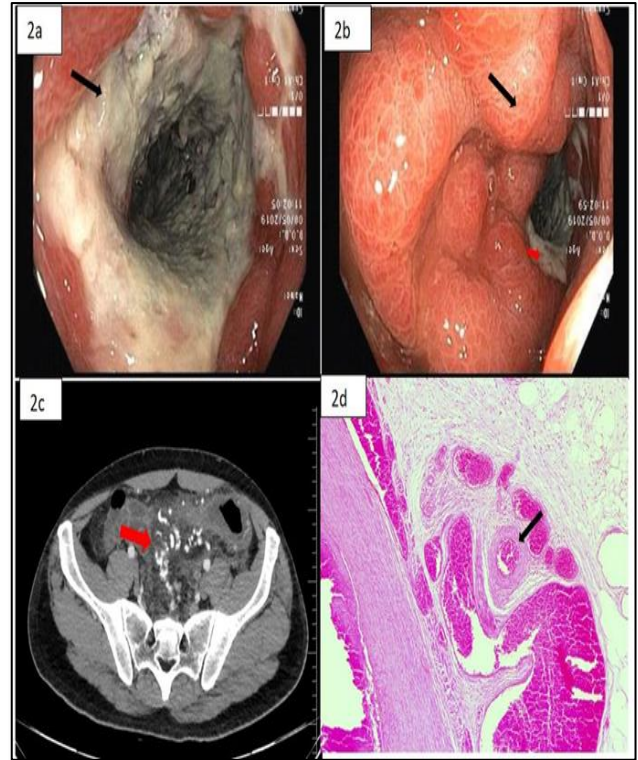


Figure 2 (A-D): Colonoscopy picture showing necrotic mucosa of descending colon, normal mucosa with transition to necrosis (red arrow), CT scan arterial phase axial section showing AVM (arrow); and HPE low power showing multiple submucosal vascular channels (arrow).

Table 1: Clinical presentation, diagnosis and management of AVM.

Patient particulars	Presenting complaint	Mode of diagnosis	Site of the disease	Treatment	Outcome and follow up
Case 1: 55 years, male	Hematochezia, shock after 1 day of admission	Colonoscopy, enteroscopy, showed only blood, CT angiography	Mid small bowel	Unsuccessful angioembolization followed by laparotomy and small bowel resection anastomosis	Doing well at 6 months
Case 2: 35 years, male	Loose stool, mucous discharge, lower abdominal pain	Colonoscopy showed ischemic ulcers from sigmoid colon to descending colon/ CT angiography	Descending and sigmoid colon	Laparotomy left colon resection and Hartmann’s procedure; bowel continuity restored after 8 weeks	Doing well at 6 months
Case 3: 76 years, male	Loose stool, increased mucous discharge, weight loss	Colonoscopy- ischemic mucosal injury, MRI pelvis, CT angiography	Rectosigmoid region	Conservative management with steroids and antisecretory agent	Partial control of symptom at 6 months

CT-Computerized tomography, MRI-Magnetic resonance imaging.

DISCUSSION

The term AVM implies the presence of an arterial feeder with an abrupt transition to veins without an intervening capillary bed. This fundamental characteristic is central to

differentiating AVM from angio-ectasias which are venous lesions and Dieulafoy’s lesions which are arterial.^{1,2} The same feature also results in diagnostic features on angiography and pathognomonic findings on histopathology of a resected specimen. On selective

arteriography, there is 'early venous drainage' due to absence of a capillary bed (Figure 1B). Histopathology will show a submucosal vascular plexus, thick-walled arteries (identified by staining of their internal elastic fibers), abruptly transitioning to thin-walled veins without an intervening capillary bed (Figure 1D).

About 20-30% of small bowel bleeds and 6% of colonic bleeds are caused by abnormal vascular channels.³ Their incidence increases with age. Most small bowel AVM are large and the presence of an arterial feeder results in acute, life-threatening hemorrhage. Treatment options depend on presentation of the patient and expertise available. Small bowel AVM can be diagnosed on CT enterography with angiography as arterially enhancing lesions with active contrast extravasation. Non-surgical treatment options include double balloon enteroscopy and argon plasma coagulation or bipolar thermal probe application and mesenteric arteriography with angioembolization. Both these options can serve as temporizing procedures to stabilize an acutely bleeding patient. The other advantage of performing these procedures is to help with intra operative localization. Endoscopic clips or tattooing and micro-coils used during embolization can help in localizing the involved segment of small bowel during surgery.⁴⁻⁶ Small bowel AVM usually require surgery for definitive management as non-surgical treatment modalities are associated with a high rate of rebleeding. Although the rate of successful immediate hemostasis achieved by embolization is reportedly high (96%), early recurrent bleeding can occur in about 20% of patients. Severe complications such as arterial dissection and bowel infarction can occur in 17%.⁷

The index patient with small bowel AVM presented with significant bleeding resulting in hemodynamic compromise and transfusion requirements. Presence of portal hypertension due to underlying hepatitis B related chronic liver disease and portal vein thrombosis complicated his management. The typical arterial enhancement pattern differentiated these from ectopic varices (Figure 1A). Due to significant bleeding and likely obscuring of vision, enteroscopy was not performed. Angioembolization was performed as the first option considering high risk associated with surgery. Within in 24 hours of the procedure patient had a significant rebleed and was taken up for surgery. There were extensive collaterals making dissection difficult, however the involved segment was identified (resected and anastomosed) as it was thickened and dusky following angioembolization (Figure 1C). Patient had post-operative hepatic decompensation with ascites leaking through the wound; he was managed with albumin and diuretic infusion and eventually recovered in three weeks and remains well on follow up without any further bleeding episodes. While secondary portal hypertension can occur due to large AVM, acute bleeding in a patient with pre-existing portal hypertension and liver disease is rare.⁸

Both patients with colonic AVM in this report presented with mucous diarrhea and abdominal discomfort, but without bleeding. Inflammatory bowel disease and colorectal cancer are the usual initial differential diagnoses. Presence of bowel congestion due to large arteriovenous channels can lead to these symptoms. Colonoscopy showed diffuse thickening, edema and mucosal necrosis of descending colon (Figure 2 A and B). Biopsy of both patients showed features of ischemic colitis; colonic AVM presenting as ischemic colitis has been reported.⁹ Cross sectional imaging (CT/MR) showed dilated tortuous vascular channels extending intramurally and onto the mesentery of the bowel (Figure 2C). There are no definitive guidelines on management of colonic AVM that present without bleeding. The younger patient had stercoring at the splenic flexure with extensive ulceration; so, he underwent colectomy followed by a staged restoration of bowel continuity and remains symptom free on follow up. The older patient had comorbidities and was managed symptomatically with antisecretory agents and antispasmodics. He reports partial symptomatic relief. Pharmacological therapy includes hormones (estrogen and progesterone), octreotide and steroids.¹⁰ All have shown variable success.

CONCLUSION

This report highlights unusual presentations of gastrointestinal AVM, highlights typical imaging and histopathology findings for diagnosis. Management of bleeding small bowel AVM is surgery while colonic AVM presenting without bleed need careful assessment and tailored management options.

Funding: No funding sources

Conflict of interest: None declared

Ethical approval: Not required

REFERENCES

1. Holleran G, Hall B, O'Regan M. Expression of Angiogenic Factors in Patients with Sporadic Small Bowel Angiodysplasia. *J Clin Gastroenterol.* 2015;49:831.
2. Danesh BJ, Spiliadis C, Williams CB, Zambartas CM. Angiodysplasia-an uncommon cause of colonic bleeding: colonoscopic evaluation of 1,050 patients with rectal bleeding and anaemia. *Int J Colorectal Dis.* 1987;2:218.
3. Naoki O, Tomonori Y, Hironori Y, Daigo A, Masanao N, Wataru H et al. Diagnosis and treatment of obscure GI bleeding at double balloon endoscopy. *Gastrointestinal Endoscopy.* 2007;66(3):S72-7.
4. Chung CS, Chen KC, Chou YH, Chen KH. Emergent single-balloon enteroscopy for overt bleeding of small intestinal vascular malformation. *World J Gastroenterol.* 2018;24:157-60.
5. Sakai E, Ohata K, Nakajima A, Matsuhashi N. Diagnosis and therapeutic strategies for small bowel

- vascular lesions. *World J Gastroenterol.* 2019;25(22):2720-33.
6. So M, Itatani Y, Obama K, Tsunoda S, Hisamori S, Hashimoto K, Sakai Y. Laparoscopic resection of idiopathic jejunal arteriovenous malformation after metallic coil embolization. *Surg Case Rep.* 2018;4:78.
 7. Strate LL, Naumann CR. The role of colonoscopy and radiological procedures in the management of acute lower intestinal bleeding. *Clin Gastroenterol Hepatol.* 2010;8:333-43.
 8. Ueda J, Yoshida H, Mamada Y, Tani ai N, Mizuguchi Y, Shimizu T et al. Successful emergency enterectomy for bleeding ileal varices in a patient with liver cirrhosis. *J Nippon Med Sch.* 2006;73:221-5.
 9. Gorospe EC, Leggett CL, Sun G. Inferior mesenteric arteriovenous malformation: An unusual cause of ischemic colitis. *Ann Gastroenterol.* 2012;25:165.
 10. Szilagy i A, Ghali MP. Pharmacological therapy of vascular malformations of the gastrointestinal tract. *Can J Gastroenterol.* 2006;20(3):171-8.

Cite this article as: Bhat LS, Bharathy KGS, Sikora SS. Intestinal arteriovenous malformations: a diagnostic and therapeutic challenge. *Int Surg J* 2022;9:1618-21.