

Case Report

Laparoscopic right hemicolectomy for rare case of caecal duplication cyst manifested as intussusception in an adult: a case report

Tarun Shetty^{1*}, Kamini Chavan²

¹Department of General Surgery, ²Department of ENT, Seth GS Medical College and KEM Hospital, Mumbai, Maharashtra, India

Received: 11 July 2022

Accepted: 03 August 2022

***Correspondence:**

Dr. Tarun Shetty,

E-mail: drtarunshetty@gmail.com

Copyright: © the author(s), publisher and licensee Medip Academy. This is an open-access article distributed under the terms of the Creative Commons Attribution Non-Commercial License, which permits unrestricted non-commercial use, distribution, and reproduction in any medium, provided the original work is properly cited.

ABSTRACT

Duplications of the alimentary tract are very rare congenital anomalies, and of which two thirds of cases manifest before the age of two years. Among duplication of alimentary tract colonic duplications are unusual, they may remain asymptomatic and present in adulthood. This report discussed a case of a 26-year-old female who presented with abdominal pain due to colocolic intussusception. Right hemicolectomy was performed for same and the diagnosis of a caecal enterogenous cyst was confirmed by histopathological exam. This report implied that although alimentary tract duplications are rare, they should be considered in any case presenting with abdominal pain. Laparoscopic right hemicolectomy can be performed for good cosmetic results, less morbidity and early recovery.

Keywords: Caecum, Duplication cyst, Colocolic intussusceptions, Laparoscopic hemicolectomy

INTRODUCTION

Duplication cysts of the intestinal tract are rare congenital anomalies which may occur in any part from esophagus to anus on the mesenteric side. They consist of well-formed tubular or spherical structures firmly attached to the intestine with a common blood supply; their walls are composed of mucous membrane, smooth muscle and serosa.

Several names were given to this malformation as enterogenous cyst, enteric cyst, inclusion cyst, enterocystoma, giant diverticulum and unusual Meckel's diverticulum.¹⁻³

This report discussed alimentary duplications of the caecal region. This was a case of an adult female who presented to the emergency room with abdominal pain due to colocolic intussusception for which right hemicolectomy was performed laparoscopically. Histopathology confirmed the diagnosis of caecal enterogenous cyst.

CASE REPORT

A 26-year-old married female, with no co-morbidities, non-smoker, presented with complain of right illiac fossa pain and vomiting for one month on and off. There were no symptoms and signs of intestinal obstructions. General condition was fair and patient was hemodynamically stable. On abdominal examination there was tenderness in RIF but rest of the abdomen was soft with no guarding or rigidity. Respiratory and cardiovascular systems were normal.

Laboratory tests showed normal haemogram and electrolyte levels. Liver and kidney function test were within normal limits. Ultrasonography (US) showed intussusceptions with a teardrop-shaped cystic mass at the tip, which had a double-layered wall consisting of a hypoechoic outer layer and an echogenic inner layer. Computed tomography (CT) demonstrated suspicious colocolic intussusception with a cystic mass at the tip of the intussusceptum, rest of the abdomen showed no

significant abnormality. Colonoscopy revealed a polypoid mass arising from caecal area protruding into the colonic lumen. But due to wide base and unknown etiology of mass colonoscopic removal was avoided.

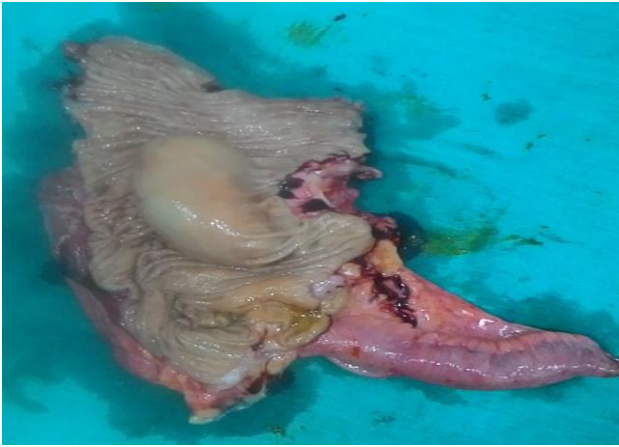

Figure 1: Gross specimen shows resected distal ileum, caecum with rounded cyst, ascending colon. The appendix appears normal.

Laparoscopy was performed which showed an invagination of caecum into ascending colon. Due to the impossibility of reducing the intussusception and unknown etiology of mass in caecum, right hemicolectomy was performed (Figure 2). Rest of the abdomen examined laparoscopically was unremarkable.

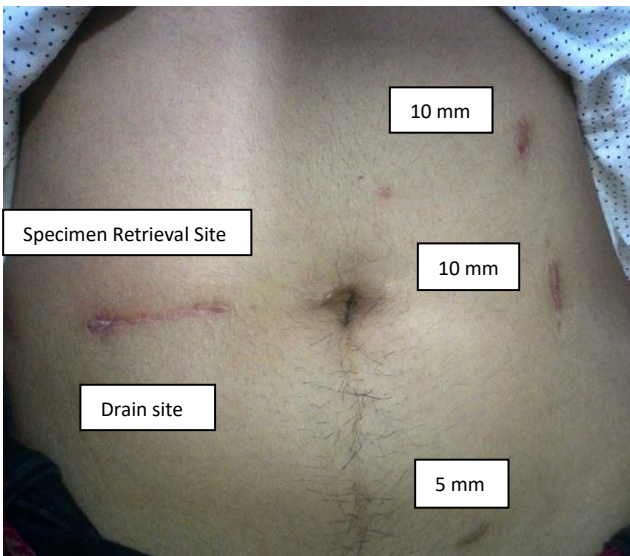


Figure 2: Post-operative laparoscopic port sites.

The postoperative course was smooth and the patient was discharged on full diet one week after the operation. The specimen on the gross examination revealed an ileocecal segment measuring 18 cm in length and 3 cm in diameter with an attached appendix 5.5 cm, there was a 7 cm rounded submucosal cecal cystic mass which was covered

by normal colonic mucosa, with glistening outer surface filled by a thick yellowish mucinous content (Figure 1). The rest of colonic and ileal mucosa looked unremarkable. The appendix appeared normal. The sections of the cyst wall revealed variable epithelial lining ranging from flattened areas to foci lined by tall columnar mucus-secreting cells to small intestinal-type epithelium with multiple lymphoid follicles in the submucosa. There is a well-defined smooth muscle layer with variable thickness and areas of dense collagenous and hyalinized connective tissue. The serosa was edematous and thickened.

DISCUSSION

The congenital intraabdominal cysts maybe classified into lymphatic or chylous cysts, enterogenous cysts, urogenital cysts and dermoid cysts or teratoids.¹

The clinical and radiologic preoperative diagnosis of ileocecal duplication cysts is difficult because the symptoms and signs may vary widely and many patients remain asymptomatic till the cyst cause serious complications as intestinal obstruction, hemorrhage, and perforation or compressing other organs. Differential diagnosis includes acute appendicitis, ovarian cyst, urinary tract infection, ureteric colic, gastroenteritis, pelvic inflammatory disease and Crohn's disease.^{1,2,4}

Our patient presented with vague abdominal pain but CT scan, colonoscopy, diagnostic laparoscopy had confirmed the cecal location of the cyst which was proven by histopathology to be an enterogenous duplication cyst, this is a very rare site for this type of intraabdominal cyst as evidenced by a large study reviewing the international literature from 1950 to 2005 on 83 reported cases of colonic duplications and another study of 46 children's cases.⁵⁻⁹

The most common imaging modalities used to diagnose duplication cysts are US and barium studies while CT and MRI are less often used.² By US the enteric duplication cyst shows a characteristic echogenic inner mucosal layer and hypoechoic outer muscular layer.¹⁰

Pathologic evaluation of enteric cecal cysts is the mainstay method of diagnosis.

In our case the gross appearance and the histopathological findings of mucosa, muscular layer and serosa in the cyst wall were typical for the diagnosis of enterogenous duplication cyst and by the good sectioning of the cyst wall and the attached bowel we could rule out any malignant changes. Our case was treated by intestinal resection with end-to-end anastomosis. However, there are other modalities of treatment, such as enucleation, marsupialization or evacuation of the cyst. The plan of the treatment should be governed by the patient's condition at the time of operation. Usually, resection of the cyst and the attached bowel is preferable to avoid recurrence or malignant transformation.^{1,5}

CONCLUSION

Duplication cysts of the caecum are very rare congenital anomalies seen often in children than adults. The variability of the clinical presentation and the wide differential diagnosis makes it difficult to diagnose preoperatively, so the clinicians should always consider this diagnosis in any case presenting with abdominal pain, perforation, intestinal obstruction or hemorrhage. Where the US is the best diagnostic tool, thorough histopathological examination is the best confirmative method of diagnosis.

Funding: No funding sources

Conflict of interest: None declared

Ethical approval: Not required

REFERENCES

1. Custer BS, Kellner A, Escue HM. Enterogenous cysts. *Ann Surg.* 1916;124(3):508-18.
2. Tong SC, Pitman M, Anupindi SA. Ileocecal Enteric Duplication cyst: Radiologic-Pathologic Correlation. *AFIP Arch.* 2002;22(5):1217-22.
3. Sieber K. Alimentary Tract Duplications. *AMA Arch Surg.* 1956;73(3):383-92.
4. Kumar1 S, Fitzmaurice1 GJ, O'Donnell ME, Brown R. Acute right iliac fossa pain: not always appendicitis or a caecal tumor: two case reports. *Cases J.* 2009;2:88.
5. Holcomb GW, Gheissari A, O'Neill JA, Shorter N. Surgical management of alimentary tract duplications. *Ann Surg.* 1989;209(2):167-74.
6. Fotiadis C, Genetzakis M, Papandreou I, Misiakos EP, Agapitos E, Zografos GC. Colonic duplication in adults: report of two cases presenting with rectal bleeding. *World J Gastroenterol.* 2005;11(32):5072-4.
7. Keum SW, Hwang MW, Na JI, Yu S, Kang DB, Oh YK. Intestinal obstruction caused by a duplication cyst of the caecum in a neonate. *Korean J Pediatr.* 2009;52(2):261-4.
8. Pati A, Mohanty HK, Subadhi PC, Dash R, Mohanty PK, Mahapatra RK. Duplication cyst of the caecum: A case report. *Indian J Surg.* 2010;72:271-2.
9. Hastings N, Norris WJ. Unusual abdominal cysts in infants and children. *California Med.* 1954;81(2):84-6.
10. Shah A, Shah A. Diagnostic dilemma of cecal duplication: *Indian Pediatrics.* 2004;41:749-50.

Cite this article as: Shetty T, Chavan K. Laparoscopic right hemicolectomy for rare case of caecal duplication cyst manifested as intussusception in an adult: a case report. *Int Surg J* 2022;9:1656-8.